

Shetur Shah *, Priyal Shah **, Rupal Vaidya ***, Zarna Sanghvi ****

ABSTRACT

Introduction: Mandibular molars may have an additional root located lingually (radix entomolaris) or buccally (radix paramolaris), which, if not diagnosed, can lead to failure of endodontic treatment. The prevalence of this anatomic variation is 4.5-11.5% in Indian populations. Awareness and understanding of the presence of unusual external and internal root canal morphology contributes to the successful outcome of the root canal treatment.

Objective and case reports: The purpose of this study was to report 2 clinical cases of endodontic treatment in mandibular molars with extra roots. Also mentioned are the modifications in the canal preparation, problems encountered during the treatment, common iatrogenic errors which occur during the treatment and factors which affect the prognosis.

Conclusion: A better understanding of the root canal morphology is essential for endodontic treatment success, as well as the use of technologic advancements including computed tomography, ultrasonic tips and the operating microscope.

Received: 23-04-2016; **Review Completed:** 19-08-2016; **Accepted:** 14-12-2016

INTRODUCTION:

The main objectives of root canal treatment are thorough debridement and complete three dimensional obturation with inert material and a fluid-tight apical seal and coronal seal. An awareness and understanding of the presence of unusual root canal morphology can thus contribute to the successful outcome of root canal treatment.

The majority of first molars are two-rooted with two mesial and one distal canal^{1,2}. In most cases the mesial root has two root canals, ending in two distinct apical foramina. Or, sometimes, these merge together at the root tip to end in one foramen. The distal root typically has one kidney-shaped root canal, although if the orifice is particularly narrow and round, a second distal canal may be present³. A number of anatomical variations have been described in the mandibular first molar: Fabra-Campos^{4,5} and Bond⁶ reported the presence of three mesial canals and Stroner⁷ noted the presence of three distal canals.

Like the number of root canals, the number of roots may also vary. An additional third root, first mentioned in the literature by Carabelli⁸, is called the radix entomolaris (RE)⁹. This supernumerary root is located disto-lingually in mandibular molars, mainly first molars (**Fig. 1A, B**). An additional root at the mesiobuccal side is called the radix paramolaris (RP) (**Fig. 1C, D**). The identification

and external morphology of these root complexes, containing a lingual or buccal supernumerary root, are described by Carlsen and Alexandersen^{10,11}.

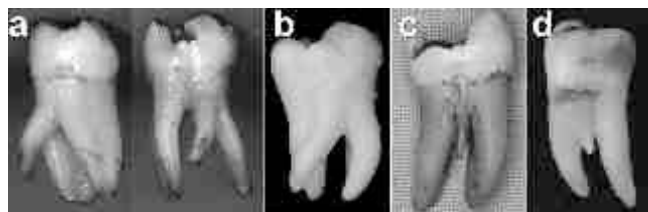

Fig 1: Clinical images of extracted mandibular molars with a radix entomolaris or paramolaris. **(A)** first molar with a radix entomolaris [distolingual view (left), lingual view (right)]. **(B)** radix entomolaris on a third molar (lingual view). **(C)** first molar with a separate radix paramolaris (buccal view). **(D)** first molar with a fused radix paramolaris (buccal view).

Although both macrostructures are rare, knowledge of their occurrence and location are important. In this report two such cases are presented. The prevalence, external morphological variations and internal anatomy of the radix entomolaris and paramolaris are described. The clinical approach to diagnosis and endodontic treatment are also discussed and illustrated.

*Post Graduate Student, **Post Graduate Student, ***Professor, **** Professor

DEPARTMENT OF CONSERVATIVE DENTISTRY & ENDODONTICS
AHMEDABAD DENTAL COLLEGE AND HOSPITAL, TA. KALOL, DIST: GANDHINAGAR, GUJARAT, INDIA.

ADDRESS FOR AUTHOR CORROSPONDENCE : DR. SHETUR SHAH, TEL: +91 9099494413

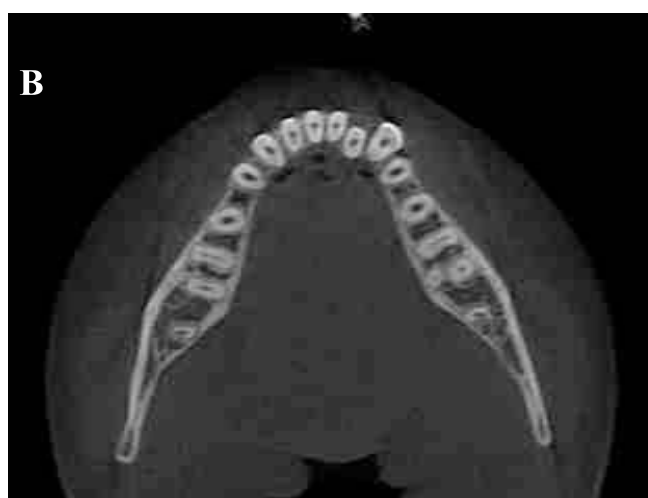
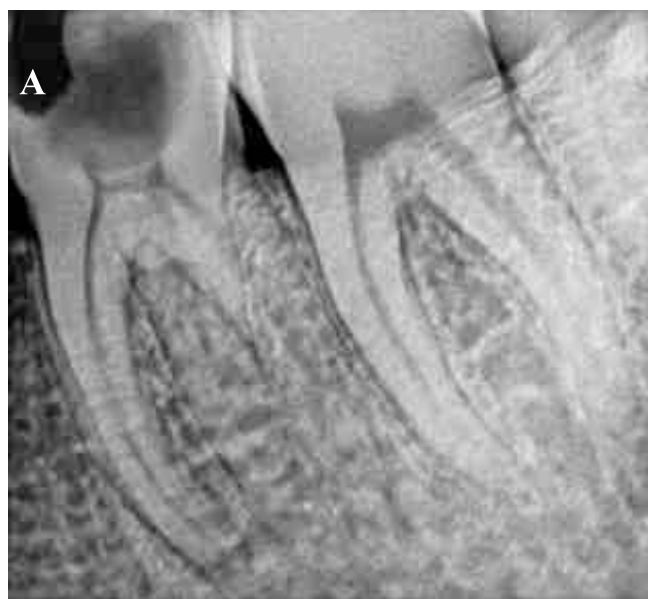Case Report 1

A 25 year old male patient reported to the Department of Conservative Dentistry and Endodontics with complaint of pain in the left lower back teeth. The patient reported a history of dull and continuous pain for the past one month, which increased in intensity on eating food and was relieved on taking medication. The extra-oral and intra-oral soft tissue examination was normal. On intra-oral hard tissue examination, the left mandibular first molar displayed deep dental carious lesion with tenderness on percussion. Thermal test was done including cold test with ice-stick, which gave a lingering response and heat test with hot burnisher, which elicited immediate sharp pain. Electrical pulp testing of the tooth elicited a delayed response. The pre-operative radiograph showed an extensive carious lesion involving the pulp and an additional root between the mesial and distal roots. CBCT was advised to confirm that the additional root was located distolingual to the mesial root. The CBCT scan slices confirmed the presence of bilateral radix entomolaris. A diagnosis of chronic symptomatic irreversible pulpitis with chronic symptomatic apical periodontitis was made and endodontic treatment was planned after eliciting a non-contributory medical history.

In the next visit, left mandibular first molar was anesthetized using 2 ml of 2% lidocaine containing 1:80,000 epinephrine and isolated under rubber dam. Access opening was done and two mesial orifices and two distal orifices were located using DG 16 explorer. To obtain a straight line access the preparation was modified to a more trapezoidal form, from the conventional triangular form. The root canals were explored with precurved K-file ISO number 15 (Dentsply Maillefer, Ballaigues, Switzerland). Working length was determined using apex locator (ProPex PiXi, Dentsply) and confirmed using radiographic method. All the canals, except the disto-ligual canal, were shaped until the ProTaper F2 rotary files (Dentsply Maillefer, Ballaigues, Switzerland). Apical patency was maintained with #20 K file. Disto-ligual canal, being curved and narrow, was shaped with #25 K-file, in order to avoid any procedural errors like separation of endodontic file, ledge formation or strip perforation. During instrumentation adequate irrigation was performed using 5.25%

sodium hypochlorite and EDTA (Glyde, Dentsply Maillefer, Ballaigues, Switzerland). These solutions were activated by EndoActivator (Dentsply, Maillefer, Ballaigues, Switzerland). Intra-canal calcium hydroxide medication was placed and Kalzinol temporary restoration was given. The patient was recalled after 1 week.

At the next appointment, the patient was asymptomatic. So, after removing the temporary restoration and calcium hydroxide intra-canal medicament, final irrigation was done with normal saline. The canals were dried with paper points. Master cone radiograph was taken. Obturation was done using AH plus sealer (Dentsply, Maillefer, Ballaigues, Switzerland) and warm vertical technique (Calamus, Dentsply, Tulsa). Post endodontic restoration was done with composite resin after 4 days and the patient was sent for crown fabrication.



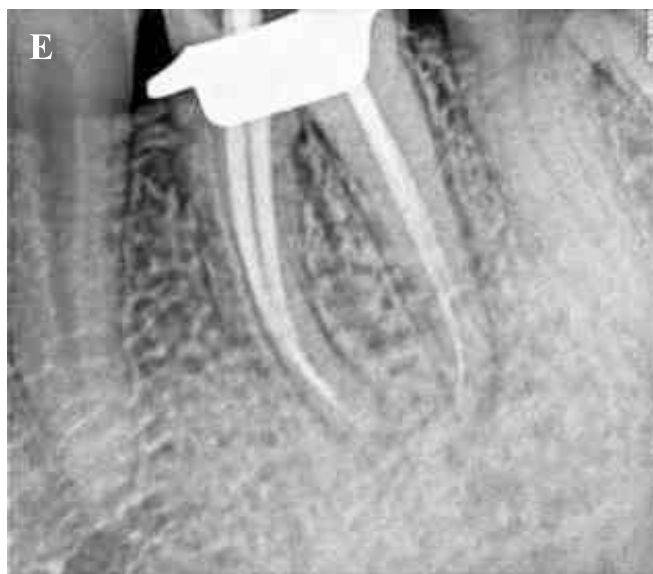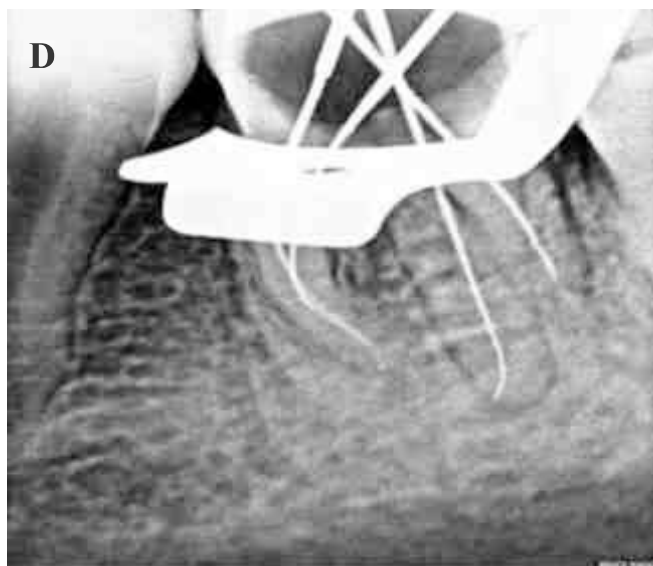

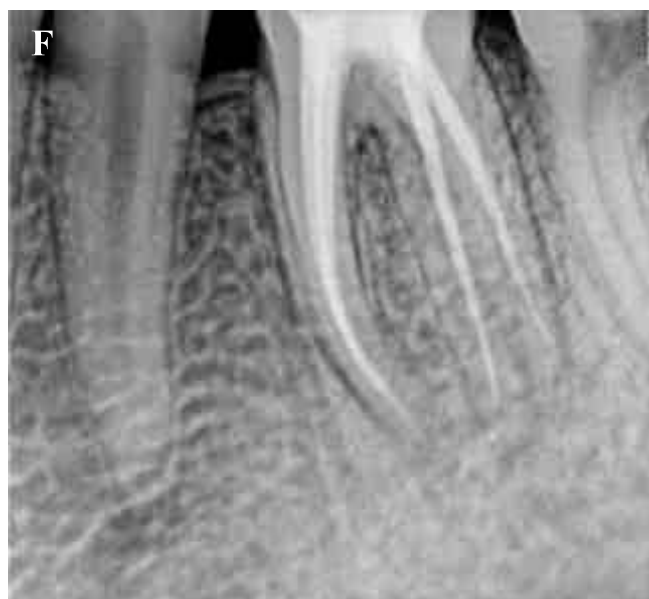
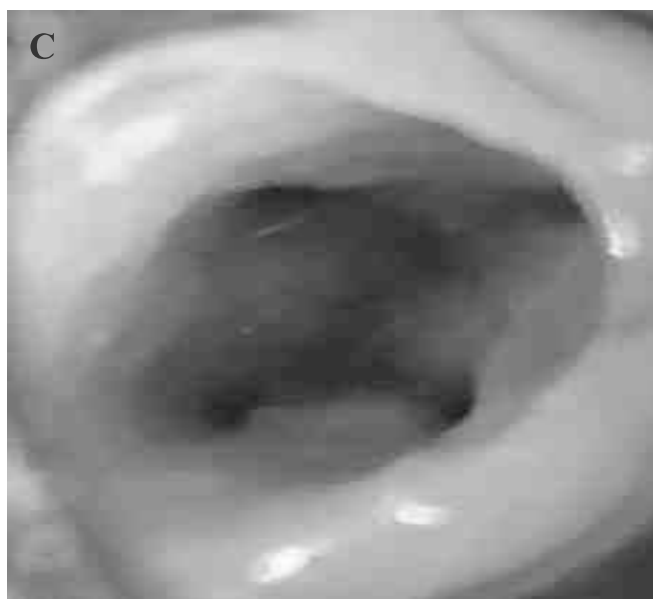Fig 2: A- Preoperative radiograph showing extensive carious lesion and radix root; B- CBCT showing clear radix entomolaris; C- Access opening showing 4 distinct canal orifices; D- Working length radiograph; E- Master cone radiograph; F- Post-operative radiograph

Case Report 2

A 35-year-old male patient was referred for endodontic treatment of the mandibular left first molar. History revealed that an initial opening of the pulp chamber had already been performed by the referring dentist to relieve acute throbbing pain before 2 months. Clinical examination of extra-oral and intra-oral soft tissues revealed non-contributory findings. Intra-oral hard tissue examination confirmed an opened mandibular left first molar. Heat test, cold test and electric pulp test gave negative response. Radiographic examination showed a distinct distal root, thus suspecting radix entomolaris. A provisional diagnosis of pulpal necrosis was done and treatment was started after confirming a non-remarkable medical history.

Access opening was done and four distinct canal orifices were found with DG-16 explorer. Initial negotiation of the root canals was performed with a K-file ISO 15 followed by coronal enlargement with ProTaper SX canal opener file.

The lengths of these canals were measured electronically and confirmed radiographically. All

canals, except the radix were shaped upto ProTaper F2 instruments. The disto-lingual canal was shaped upto #25 K-file. The canals were cleaned with sodium hypochlorite solution (5.25%) and EDTA (Glyde, Dentsply, Maillefer, Ballaigues, Switzerland), EndoActivator was used for their activation. Intra-canal calcium hydroxide medicament was given, followed by Kalzinol temporary restoration.

In the next appointment, after 5 days, the temporary

restoration and intra-canal calcium hydroxide were removed. A final rinse of normal saline was done followed by drying of canals by paper points. The master cone selection was confirmed radiographically, with 30 degrees angulation from the mesial. All canals were filled with warm vertical technique (Calamus, Dentsply) and AH26 sealer. Post endodontic restoration of silver amalgam was given. The patient was then referred for crown fabrication.

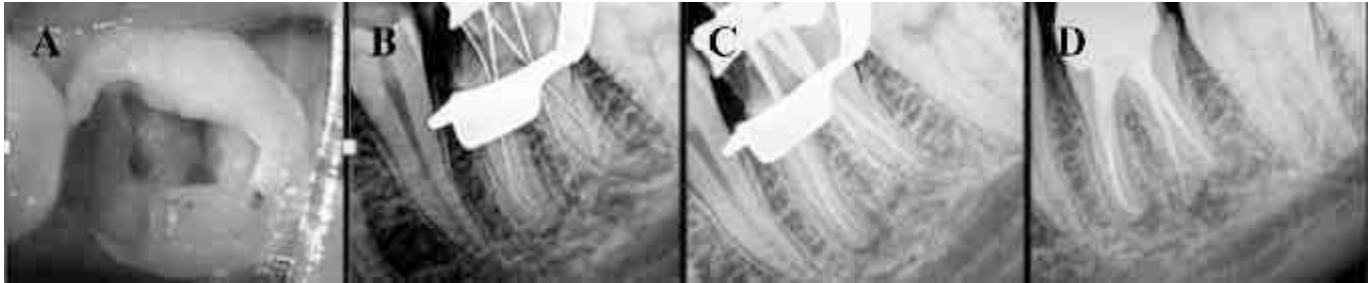

Fig 3: A- Access opening showing 4 distinct canal orifices; B- Working length radiograph; C- Master cone radiograph; D- Postoperative radiograph

Discussion

The presence of a separate RE in the first mandibular molar is associated with certain ethnic groups. In African populations a maximum frequency of 3% is found^{12,13}, while in Eurasian populations the frequency is less than 5%¹⁴. In Chinese populations, reports have noted that the RE occurs with a frequency that ranges from 5% to more than 30%¹⁴⁻²⁰. Because of its high frequency in these populations, the RE is considered to be a normal morphological variant (eumorphic root morphology). In Caucasians the RE is not very common and, with a maximum frequency of 3.4 to 4.2%^{21,22}, is considered to be an unusual or dysmorphic root morphology. In Indians, it has been reported in 4.5-11.5% of the population²³.

The etiology behind the formation of the RE is still unclear. In dysmorphic, supernumerary roots, its formation could be related to external factors during odontogenesis, or to penetrance of an atavistic gene or polygenetic system (atavism is the reappearance of a trait after several generations of absence). In eumorphic roots, racial genetic factors influence the more profound expression of a particular gene that results in the more pronounced phenotypic manifestation^{19,24}. Curzon suggested that the 'three-rooted molar' trait has a high degree of genetic penetrance as its dominance was reflected in the fact

that the prevalence of the trait was similar in both, pure Eskimo and Eskimo/ Caucasian mixes²⁵.

An RE can be found on the first, second and third mandibular molar, occurring least frequently on the second molar²⁶. Some studies report a bilateral occurrence of the RE from 50 to 67%^{27,18}.

Bolk²⁸ reported the occurrence of a buccally located additional root: the RP. This macrostructure is very rare and occurs less frequently than the RE. The prevalence of RP, as observed by Visser²⁶, was found to be 0% for the first mandibular molar, 0.5% for the second and 2% for the third molar. Other studies have, however, reported RP in first mandibular molars^{11,13}.

In general, the RE is smaller than the distobuccal and mesial roots and can be separate from, or partially fused with, the other roots. A classification by Carlsen and Alexandersen¹⁰ (Fig. 5) describes four different types of RE according to the location of the cervical part of the RE: types A, B, C and AC. Types A and B refer to a distally located cervical part of the RE with two normal and one normal distal root components, respectively. Type C refers to a mesially located cervical part, while type AC refers to a central location, between the distal and mesial root components. This classification allows for the identification of separate and nonseparate RE.

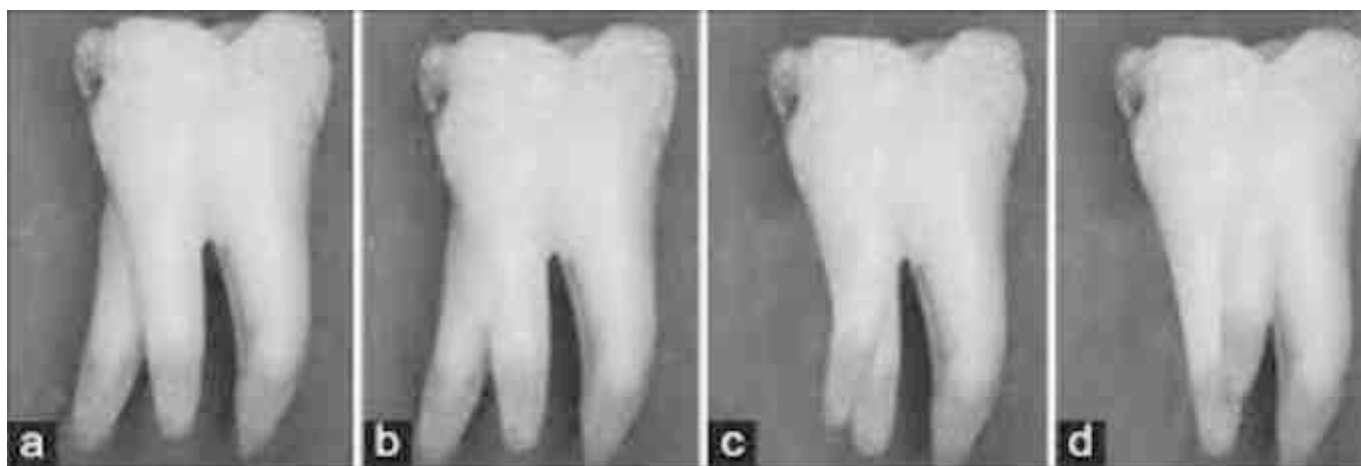


Fig 5: Carlsen and Alexandersen classification of Radix Entomolaris

According to the classification of De Moor et al.²⁹, based on the curvature of the separate RE variants in bucco-lingual orientation, three types can be identified. Type I refers to a straight root/root canal, while type II refers to an initially curved entrance which continues as a straight root/root canal. Type III refers to an initial curve in the coronal third of the root canal and a second curve beginning in the middle and continuing to the apical third.

The RP is located (mesio) buccally. This additional root can be separate or non-separate (**Fig. 1C, D**). Carlsen and Alexandersen¹¹ (**Fig. 6**) describe two different types: types A and B. Type A refers to an RP in which the cervical part is located on the mesial root complex; type B refers to an RP in which the cervical part is located centrally, between the mesial and distal root complexes. An additional cusp was present on the buccal side. A similar observation has been made in other reports, i.e. an increased number of cusps is not necessarily related to an increased number of roots; however, an additional root is nearly always associated with an increased number of cusps, and with an increased number of root canals^{13,30,31}.

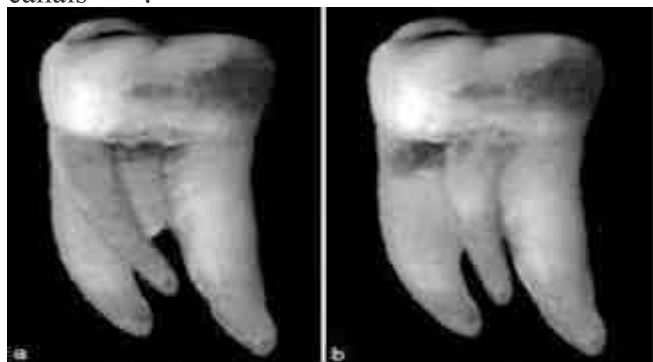

Fig 6: Carlsen and Alexandersen Classification of Radix Paramolaris

The presence of an RE or an RP has clinical implications in endodontic treatment. An accurate diagnosis of these supernumerary roots can avoid complications or a 'missed canal' during root canal treatment. A superimposition of both roots can appear on the preoperative radiograph, resulting in an inaccurate diagnosis. A thorough inspection of the preoperative radiograph can indicate the presence of a 'hidden' RE. To reveal the RE, a second radiograph should be taken from a more mesial or distal angle (30 degrees). This way an accurate diagnosis can be made in the majority of cases.

Apart from a radiographical diagnosis, clinical inspection of the tooth crown and analysis of the cervical morphology of the roots by means of periodontal probing can facilitate identification of an additional root. An extra cusp (tuberculum paramolare) or more prominent occlusal distal or distolingual lobe, in combination with a cervical prominence or convexity, can indicate the presence of an additional root.

The location of the orifice of the root canal of an RE has implications on the access cavity shape. The orifice of the RE is located disto- to mesiolingually from the main canal or canals in the distal root, so, modification of the triangular access cavity to the (disto) lingual results in a more rectangular or trapezoidal outline form. Visual aids such as a dental operating microscope (DOM) or an intra-oral camera can be useful for locating this canal. A dark line on the pulp chamber floor can indicate the precise location of the RE canal orifice. The distal and lingual pulp chamber wall can be explored with an angled probe to reveal overlying dentin or pulp

roof remnants masking the root canal entrance. The calcification, which is often situated above the orifice of the RE, has to be removed for a better view and access to the RE. An initial relocation of the orifice to the lingual is indicated to achieve straight-line access. However, to avoid perforation or stripping in the coronal third of a severe curved root, care should be taken not to remove an excessive amount of dentin on the lingual side of the cavity and orifice of the RE.

A severe root inclination or canal curvature, particularly in the apical third of the root (as in a type III RE), can cause shaping aberrations such as straightening of the root canal or a ledge, with root canal transportation and loss of working length resulting. Unexpected complications such as instrument separation do occur, and are more likely to happen in an RE with severe curvature or narrow root canals. Therefore, after relocation and enlargement of the orifice of the RE, initial root canal exploration with small files (size 10 or less) and curvature determination, and the creation of a

glide path before preparation, are step-by-step actions that should be taken to avoid procedural errors.

Conclusion

Clinicians should be aware of these unusual root morphologies in the mandibular first molars in Caucasian people. The initial diagnosis of a radix entomolaris or paramolaris before root canal treatment is important to facilitate the endodontic procedure, and to avoid 'missed' canals. Preoperative periapical radiographs exposed at two different horizontal angles are required to identify these additional roots. Knowledge of the location of the additional root and its root canal orifice will result in a modified opening cavity with extension to the distolingual.

The morphological variations of the RE in terms of root inclination and root canal curvature demand a careful and adapted clinical approach to avoid or overcome procedural errors during endodontic therapy.

REFERENCES:

1. Barker BC, Parson KC, Mills PR, Williams GL. Anatomy of root canals. III. Permanent mandibular molars. *Aust Dent J* 1974;19:403–13.
2. Vertucci FJ. Root canal anatomy of the human permanent teeth. *Oral Surg Oral Med Oral Pathol* 1984;58:589–99.
3. Thoden Van Velzen SK, Wesselink PR, De Cleen MJH. *Endodontologie*, 2nd ed. Bohn Stafleu Van Loghum, Houtem/Diegem, 1995:142–3.
4. Fabra-Campos H. Unusual root anatomy of mandibular first molars. *J Endod* 1985;11:568–57.
5. Fabra-Campos H. Three canals in the mesial root of mandibular first permanent molars: a clinical study. *Int Endod J* 1989;22:39–43.
6. Bond JL. Clinical management of middle mesial root canals in mandibular molars. *J Endod* 1988;14:312–4.
7. Stroner WF. Mandibular first molar with three distal canals. *Oral Surg* 1984;57:554–7.
8. Carabelli G. *Systematisches Handbuch der Zahnheilkunde*, 2nd ed. Vienna: Braumullerund Seidel, 1844:114.
9. Bolk L. Bemerkungen über Wurzelvariationen am menschlichen unteren Molaren. *Zeitung für Morphologie und Anthropologie* 1915;17:605–10.
10. Carlsen O, Alexandersen V. Radix entomolaris: identification and morphology. *Scan J Dent Res* 1990;98:363–73.
11. Carlsen O, Alexandersen V. Radix paramolaris in permanent mandibular molars: identification and morphology. *Scan J Dent Res* 1991;99:189–95.
12. De Moor RJG, Hommez GMG. The long-term sealing ability of an epoxy resin root canal sealer used with five gutta percha obturation techniques. *Int Endod J* 2002;35:275–82.
13. Sperber GH, Moreau JL. Study of the number of roots and canals in Senegalese first permanent mandibular molars. *Int Endod J* 1998;31:112–6.
14. Tratman EK. Three-rooted lower molars in man and their racial distribution. *Br Dent J*

- 1938;64:264–74.
15. Pedersen PO. The East Greenland Eskimo dentition. Numerical variations and anatomy. A contribution to comparative ethnic odontography. Copenhagen: Meddeleserom Gronland 1949;104:140–4.
 16. Turner CG 2nd. Three-rooted mandibular first permanent molars and the question of Am Indian origins. *Am J Phys Anthropol* 1971;34:229–41.
 17. Curzon MEJ, Curzon AJ. Three-rooted mandibular molars in the Keewatin Eskimo. *J Can Dent Assoc* 1971;37:71–2.
 18. Yew SC, Chan K. A retrospective study of endodontically treated mandibular first molars in a Chinese population. *J Endod* 1993;19:471–3.
 19. Reichart PA, Metah D. Three-rooted permanent mandibular first molars in the Thai. *Community Dent Oral Epidemiol* 1981;9:191–2.
 20. Walker T, Quakenbush LE. Three rooted lower first permanent molars in Hong Kong Chinese. *Br Dent J* 1985;159:298–9.
 21. Curzon ME. Three-rooted mandibular permanent molars in English Caucasians. *J Dent Res* 1973;52:181.
 22. Ferraz JA, Pecora JD. Three-rooted mandibular molars in patients of Mongolian, Caucasian and Negro origin. *Braz Dent J* 1993;3:113–7.
 23. Chandra SS, Chandra S, Shankar P, Indira R. Oral Surg Oral Med Oral Pathol Oral Radiol Endod. 2011 Sep;112(3):e77-82
 24. Ribeiro FC, Consolaro A. Importancia clinica y antropologica de la raiz distolingual en los molars inferiores permanentes. *Endodoncia* 1997;15:72–8.
 25. Curzon ME. Miscegenation and the prevalence of three-rooted mandibular first molars in the Baffin Eskimo. *Community Dent Oral Epidemiol* 1974;2:130–1.
 26. Visser JB. Beitrag zur Kenntnis der menschlichen Zahnwurzelformen. *Hilversum: Rotting* 1948;49–72.
 27. Steelman R. Incidence of an accessory distal root on mandibular first permanent molars in Hispanic children. *J Dent Child* 1986;53:122–3.
 28. Bolk L. Welcher Gebireihe gehören die Molaren an *Z Morphol Anthropol* 1914;17:83–116.
 29. De Moor RJ, Deroose CA, Calberson FL. The radix entomolaris in mandibular first molars: an endodontic challenge. *Int Endod J* 2004;37:789–99.
 30. Carlsen O, Alexandersen V. Radix paramolaris and radix distomolaris in Danish permanent maxillary molars. *Acta Odontol Scand* 1999;57:283–9.
 31. Brabant H, Klees L, Werelds RJ. Anomalies, mutilations et tumeurs des dents humaines. Paris, France: Editions Julien Prelat 1958.