

Rutu Jani*, Parul Bhatia**, Abhinandan Gokhroo***, Prutha Nemade****

ABSTRACT

Osteoma is a benign tumor composed of mature compact or cancellous bone. Osteoma arises from the surface of the bone (periosteal) or is located in medullary bone (endosteal) as a pedunculated or sessile mass. They are common lesions in maxillofacial region mainly in frontal, ethmoidal and maxillary sinuses. In jaws, most common site is mandible and is rarely seen in maxilla. This is a case report of osteoma of maxilla in a 37 year old female patient.

KEYWORDS: Osteoma of maxilla, compact, cancellous, exostosis.

Received: 26-06-2015; **Review Completed:** 28-07-2015; **Accepted:** 28-10-2015

INTRODUCTION:

An osteoma is a benign osteogenic tumor characterized by compact or cancellous bone proliferation. Osteoma was described as a specific entity by Jaffe in 1935. It may be classified as peripheral, central, or extraskeletal. A peripheral osteoma arises from the periosteum, a central osteoma from the endosteum, and an extraskeletal osteoma in the soft tissue.¹ The pathogenesis of osteoma is not completely known. They are referred to as developmental anomalies, true neoplasms, hamartomas or reactive lesions triggered by trauma, muscle traction, or infection. Infiltration of interdental bone and abnormal histological bone structure might support the neoplastic nature of this lesion. They generally occur between second and fifth decades of life, being more common in males.^{1,2}

Osteomas are found mainly in the craniofacial bones. Osteomas occur most frequently in the paranasal sinuses.^{1,2} Other locations include the orbital wall, temporal bone, pterygoid processes, and external ear canal. As noted in previous reports in the literature, a solitary osteoma of the jaw bones is quite rare, involving the mandible more often than the maxilla. The most frequent sites affected in the mandible are the posterior body followed by the condyle, angle, ascending ramus, coronoid process, anterior body and sigmoid notch. The only symptom of a developing osteoma is asymmetry caused by bony hard swelling on the jaw.³

As most of the osteomas of the maxilla are asymptomatic they usually are diagnosed in a

routine radiographic examination. Radiographically, osteomas characterized by a single or multiple well-circumscribed radiopaque areas. Histologically, osteomas consist of mature, lamellar bone with abundant fibro fatty marrow between bony trabeculae. Exostosis, osteochondroma, osteoblastoma osteoid osteoma, ossifying fibroma, odontoma are differential diagnosis of osteoma. Association between maxillofacial osteomas, cutaneous sebaceous cysts, multiple supernumerary teeth and colorectal polyposis has also been reported as Gardner's syndrome.^{3,4} Usually no treatment is required for osteoma until it does not cause any obstruction in function. If required, surgical excision is done.⁴

Osteoma of maxilla is very rare and generally asymptomatic.⁴ The present case report is a rare case of osteoma of maxilla in a 37 year female.

CASE REPORT

A 37 year old female patient reported to Oral Medicine and Radiology Department with chief complain of swelling on right side of upper jaw for last three years. The swelling was smaller in size initially and increased to present size. Apart from disfigurement because of swelling, patient had no other complaint. There was no history of trauma or any systemic disease. There was no relevant family history.

On extra oral examination there was no abnormality detected and face was bilaterally symmetrical (Figure - 1).

* Senior Lecturer, ** Professor, *** PG Student, **** PG Student

ORAL MEDICINE & RADIOLOGY DEPARTMENT, AHMEDABAD DENTAL COLLEGE & HOSPITAL, GUJARAT.

ADDRESS FOR AUTHOR CORRESPONDENCE : Dr. ABHINANDAN GOKHROO, TEL: +91 8238341778

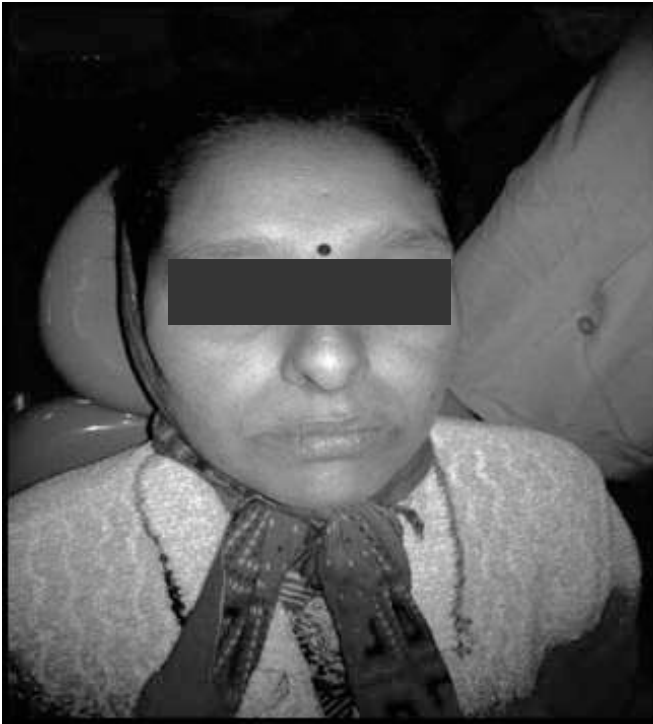

Figure-1: Profile of patient showing bilateral symmetry

On intra oral examination. there was a single 3 cm by 2 cm sized oval swelling present on the right side of facial aspect of maxillary alveolar ridge extending anteroposteriorly from mesial of 12 to distal of 14 and superoinferiorly from mucobuccal fold to marginal gingiva (Figure-2). The overlying skin was normal in colour. The swelling was bony hard, non-tender and fixed to the underlying structure.

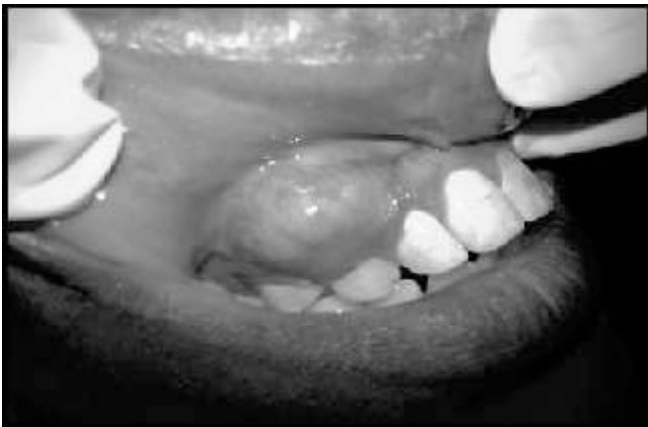

Figure-2: Intraoral photograph showing well defined growth on facial surface of the maxilla

As the swelling was bony hard in consistency an intra-oral periapical radiograph(IOPA) in relation with 12,13,14 region and maxillary cross sectional

occlusal radiograph were taken. IOPA in relation to 12, 13, 14 showed no pathology. Maxillary cross sectional occlusal radiograph showed a well circumscribed oval expansion on buccal aspect of 12, 13, 14 showed normal trabecular bone pattern and a corticated border (Figure-3). A clinico-radiographic diagnosis of osteoma was made and bony exostosis, osteochondroma were kept as differential diagnosis.

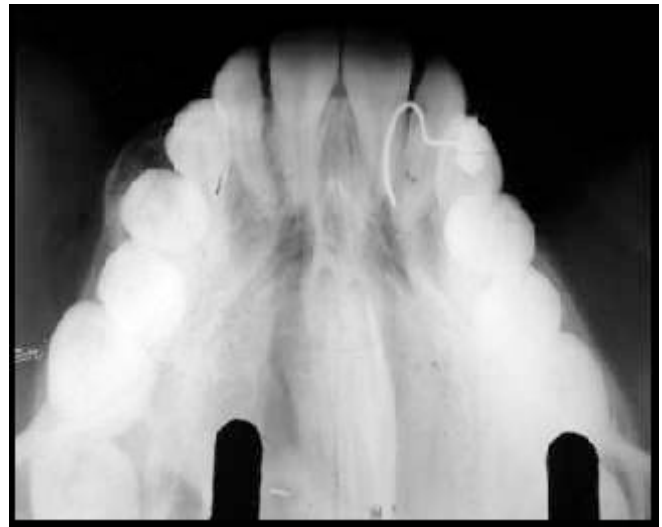

Figure -3: Maxillary cross-sectional occlusal radiograph showing a large well defined radiopacity

As patient was concerned about disfigurement surgical removal was advised. All laboratory findings were within normal limits. The patient was prepared for surgery under local anesthesia and the bony mass was approached by reflection of full thickness flap in maxillary anterior region. The lesion was spherical in shape and attached to the underlying bone. With the help of round bur punch holes were drilled at the periphery of the lesion. Then the entire lesion was excised using punch holes as reference and specimen was sent for microscopic examination (Figure-4). The cortical plate of the body of the maxilla was smoothed with a vulcanite bur under copious saline irrigation. Postoperative recovery was uneventful.

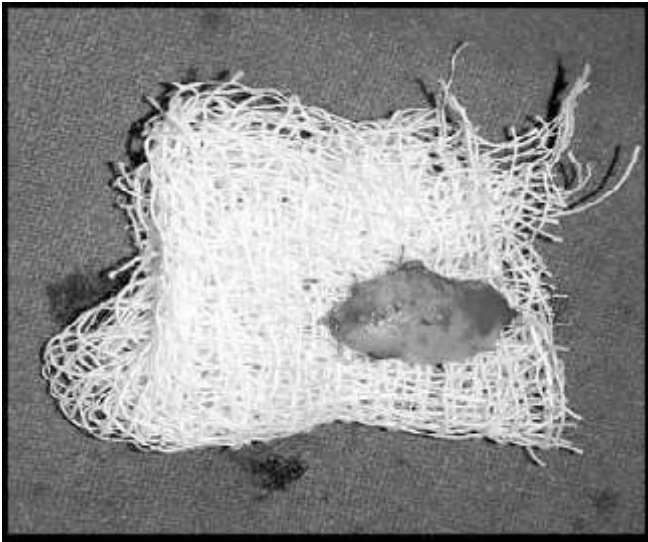


Figure- 4: Excised specimen after surgical removal

For histological examination of the specimen decalcified section was made and stained with Hematoxylin & Eosin(Figure-5). It revealed mature dense spicules of compact bone intermingled with myxomatous tissue in some areas. Large number of blood vessels, extravasated RBC'S were also seen. Based on the above features the histopathological diagnosis of osteoma was confirmed.

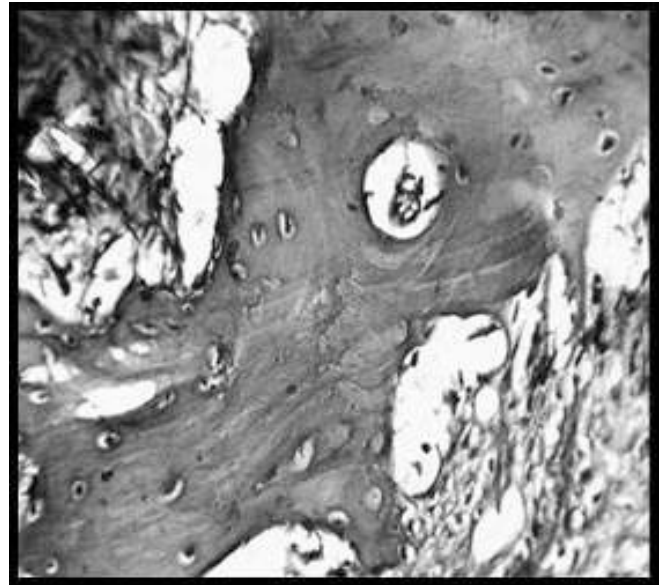
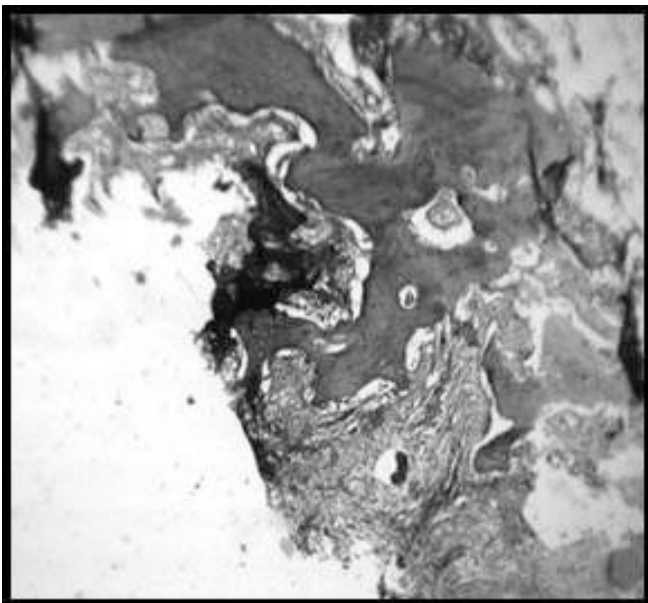


Figure -5(a): microscopic features of excised specimen revealed mature dense spicules of compact bone intermingled with myxomatous tissue in some areas (haematoxylin-eosin 10x, 40x)

DISCUSSION

Osteoma is described as a benign neoplasm of bone composed of mature compact or cancellous bone in an endosteal or periosteal location. The central osteoma arises from the endosteum, the peripheral osteoma from the periosteum and the extraskeletal soft tissue osteoma usually develops within the muscle.³ Osteomas are most common in old age but in present case the patient is middle aged individual. Osteoma has male predilection for compact variety and for female with cancellous variety which is not in accordance with the present case as patient is a female with compact variety of osteoma.⁵

The most common site is the frontal sinus, followed by the ethmoidal and maxillary sinus. Osteomas are more frequent in the mandible than in the maxilla where as in present case it was situated on maxilla.^{1,4}

The osteomas are generally asymptomatic, slow growing masses which are bony hard in consistency.⁵ In the above case, all these features were present which is in accordance with the literature. Radiographically, osteomas are easy to recognize because of their classic radiographic findings. The internal structure of lesion was clearly seen with normal bone pattern and a sclerotic border which is a classic feature of osteoma.

The differential diagnosis of osteoma are exostosis, osteoblastoma and osteoid osteoma, ossifying

fibromas, odontomas. Exostosis are developmental in origin and usually occur in young patients.

Osteoblastomas and osteoid osteomas are more frequently painful and grow more rapidly than osteomas. Temporomandibular joint is most common site for osteoblastoma.^{6,7} The borders of central ossifying fibromas are well-defined and a thin radiolucent line may separate it from the surrounding bone whereas osteoma of the mandible is a classically well-circumscribed, round or oval, mushroom-like radiopaque mass with distinct borders.^{8,9} A complex odontoma is present as a well-defined radiopacity situated in bone, but with a density that is greater than bone and equal to or greater than that of a tooth but in present case the density is comparable to bone. It is also surrounded by a narrow radiolucent rim. The present case had bony hard swelling but skin lesions like sebaceous cyst or multiple impacted teeth are absent.^{10,11} Thus, Gardner's syndrome was ruled out. Surgical intervention is indicated only if it becomes large enough to cause facial asymmetry and functional impairment. Surgical excision is usually simple in

osteoma. Recurrence of osteoma after surgical excision is extremely rare and malignant transformation of osteoma has not been reported in literature.^{1,4} Thus in present cases, surgical excision was done as patient was concerned about disfigurement.

CONCLUSION

Osteomas a common benign osteogenic lesion occurring in oral and maxillofacial region but occurs rarely in maxilla. The possibility of osteoma should be kept in mind as a differential diagnosis for any peripheral, solitary, bony hard, slow growing painless swelling encountered in oral and maxillofacial region. All differential diagnosis discussed above should be considered in case of any such bony hard swelling and especially in case of maxilla the swelling should be examined keeping in mind osteoma as one of the differential diagnosis as it is rare in maxilla and can be misdiagnosed and investigated. This case report is an addition to very few cases of osteoma of maxilla reported till now.

REFERENCES

1. Gayathri Goudar, Ravi Kumar.R, Manjunath G.A, Jyothi Mahadesh. Osteoma of the Mandible. *JDent Sci Res* 2011; 2(1):116-22.
2. Emel Bulut, Aydan Acikgoz, Bora Ozan, Omer Gunhan. Large Peripheral Osteoma of the Mandible: A Case Report. *Int J Dent* 2010; 4(2):1155.
3. Buccal sided mandibular angle exostosis. A rare case report. Salman Basha, Sunil.C.Dutt. *Cont Clin Dent* 2011; (2)3: 237-9
4. Göksel Şimşek Kaya, Mehmet Melih Ömezli, Sare Şipal, Ümit Ertaş. Gigantic Peripheral Osteoma of the Mandible: A Case Report. *J Clin Exp Dent* 2010; 2(3):160-2.
5. Alejandro Donohué-Cornejo, Laura Elena Franco Garrocho, Surisadey Albarrán, Vergara, Luis Alberto, Gaitán Cepeda. Active Giant Peripheral Osteoma of the Mandible. *J Clin Exp Dent* 2010; 2(4):212-4
6. ID Roy. Peripheral Osteoma of Mandible. *Med J Armed Forces Ind* 2008; 64(4): 385-6.
7. A Morreti et al. Osteoma of Maxillary sinus. A Case report. *Otorhinolaryngol Ital.* 2004; 24(2):219-22.
8. Amit Kumar Tamrakar, Syed Ansar Ahmad, Manu Rathee. Surgical removal of palatal bony exostosis: a case report. *Annals Dent Spec* 2014; 2(3): 110-2.
9. K. Smitha, G.P. Smitha. Alveolar exostosis – revisited: A narrative review of literature. *Saudi J Dent Res* 2015; 6(2): 67–72.
10. A.R Chaudhary, Bhargav Selarka, Bhavin Dudhia, Purv Patel. Peripheral osteoma with multiple exostosis of the Mandible – A case report. *J Ahmed Dent Coll Hosp* 2013; 4(1):34-6.
11. Namish Batra, Renu Batra, Gaurav Singh, Amit Gaur. Peripheral osteoma of maxilla: A case report. *Natl J Maxillofac Surg* 2014; 5(2):240-2.
12. P. Vibhakar, A Yeolekar, S Pal. Osteoma of mandible: A Case Report. *Ban J Dent Res Edu* 2014; 4(1): 39-41.