

\*Bhavya Trivedi, \*\*Sonali Mahadevia, \*\*\*Margee Turakhiya, \*\*\*\*Aatman Joshipura

### ABSTRACT

We are in the process of discovery new vistas for technological advances in terms of various appliances with a vision of making compliance free successful orthodontic treatment. Due to improved technology, the enigma of treating the class II syndrome is palliated. "Out of the box" thinking has become a norm to treat certain situations that were not corrected in non-complaint patients. Fixed functional appliances are valuable tools introduced to assist in the correction of skeletal class II malocclusion with mandibular retrognathia at the deceleration stage of growth for achieving stable result. In this direction a case is reported of a patient having the above conditions, undergoing the orthodontic treatment by using Forsus fixed functional appliance. Joining hands with technology is a win win situation for both the patient and the orthodontist.

**Keywords:** Forsus, Class II malocclusion, Mandibular Retrognathism

**Received:** 07-03-2014; **Review Completed:** 23-05-2014; **Accepted:** 06-09-2014

### INTRODUCTION:

Every orthodontist at some point in his clinical practice has faced the dilemma of how 'best' to manage class II malocclusion. Treatment of class II malocclusion has always been a mind boggler to the orthodontic fraternity. To obtain the foremost result with skeletal class II malocclusion, the Etiology and diagnosis of malocclusion is the key for achieving the predictable and stable result. As we move in the new millennium, there is still controversy about management of class II patients with maxillary prognathism, mandibular retrognathism or both.

Case reports of skeletal class II malocclusion with mandibular retrognathism at the end stage of the growth treated by the fixed functional appliance, Forsus™. In this case camouflage would have been attempted, by removing upper premolars without any maxillary dento alveolar excess can lead to detrimental changes in the soft tissue profile of the patient.

The Forsus Fatigue-Resistant Device (FRD) is an interarch push spring that produces about 200 gm of force when fully compressed. The FRD can intrude the maxillary first molars and thus help in correcting

class II malocclusion without opening the bite.

The distal end of FRD's push rod inserts into telescopic cylinders and a hook on the mesial end is crimped directly to the arch wire near the canine or the premolar brackets. The telescopic cylinders consist of inner and outer sliding tubes surrounded by an open coil spring. An eyelet at the distal end of the cylinders is connected to the maxillary molar head gear tube with L pin.

### DIAGNOSIS AND ETIOLOGY:

A 14 year old male patient complained of irregularly placed upper front teeth. He was not satisfied with his facial appearance.




Fig. 1 Pre-treatment extraoral photographs

\* Professor, \*\* Head of the department, \*\*\* P.G. Student, \*\*\*\* Senior Lecturer

DEPARTMENT OF ORTHODONTICS AND DENTOFACIAL ORTHOPEDIC, AHMEDABAD DENTAL COLLEGE AND HOSPITAL, TA. KALOL, DIST. GANDHINAGAR GUJARAT, INDIA.

ADDRESS FOR AUTHOR CORRESPONDENCE : DR. BHAVYA TRIVEDI, TEL: +91 9825443347

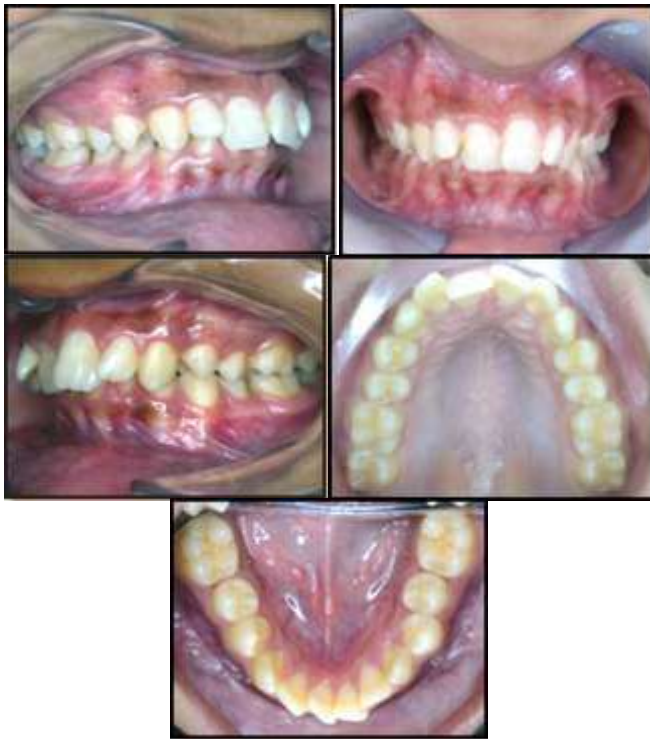

Fig. 2 Pre-treatment intraoral photographs

Clinical examination (fig.1) showed brachycephalic facial form with horizontal growth pattern, convex profile, acute nasolabial angle, deep mentolabial sulcus. On Intraoral examination (fig. 2) molar relation showed class II molar and canine relation on both sides and increased overbite, crowding in upper and lower arch.

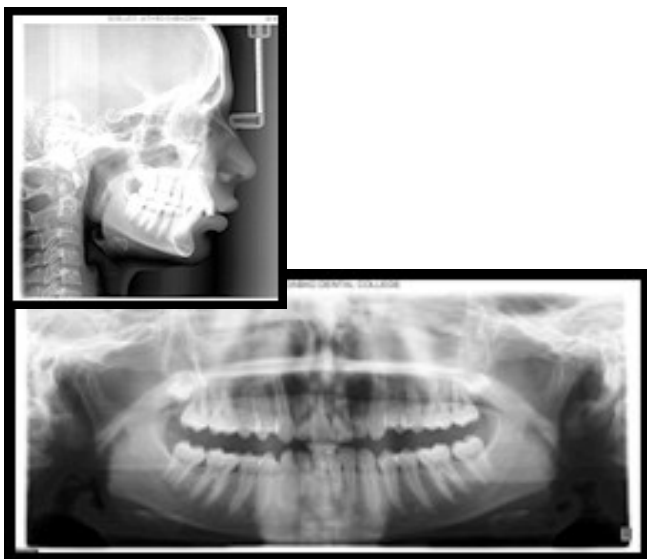


Fig. 3 Pre-treatment Lateral Cephalogram Fig. 4 Pre-treatment orthopantomogram

Cephalogram (fig. 3) revealed skeletal class II malocclusion with retrognathic mandible. On radiographic examination of cervical vertebrae, 25% of adolescence growth was still expected according to Hassel & Farman (1995) system of skeletal maturation.

**TREATMENT OBJECTIVES:-**

The objectives of treatment for this patient were to correct the retrognathic mandibular position, to achieve class I molar and canine relation, to correct rotated tooth, proclined upper anterior teeth, and establish stable functional occlusion with ideal anterior overbite and overjet, Coinciding dental and facial midlines to harmonize the shape of the dental arch and orofacial functions.

**TREATMENT ALTERNATIVES:-**

Non orthodontic extraction therapy with Orthognathic surgery for mandibular advancement by BSSO can be performed. But patient had still some growth left.

In this case if camouflage was another alternative. But since there was no maxillary dento alveolar excess, it could have led to detrimental changes in the soft tissue profile of the patient.

Some authors suggested using class II elastic in skeletal class II pattern but it brings more dento alveolar change than skeletal.

**TREATMENT PROGRESS:-**

Treatment started with PEA technique and MBT prescription 0.022 slot brackets; alignment was carried out in both arches.

For Forsus placement, length was measured from distal end of upper first molar to distal end of lower canine, and placed along with anterior buccal root torque in lower arch and crimpable hook distal to canine in both sides were as stopper for continuous 5 months.

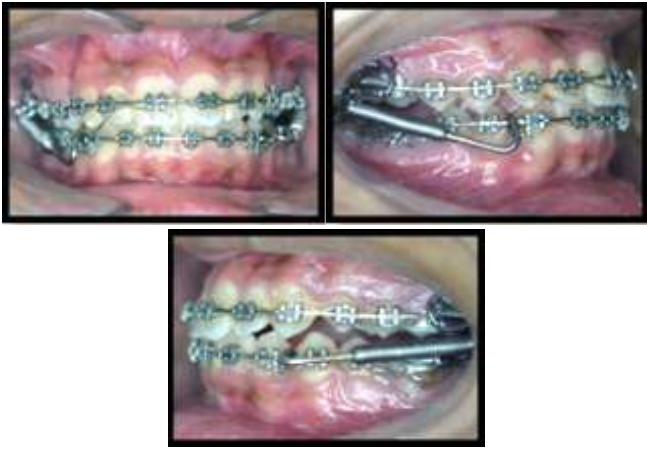

Fig. 5 Forsus placed after alignment of arches.




Fig. 6 Post-treatment extraoral photographs

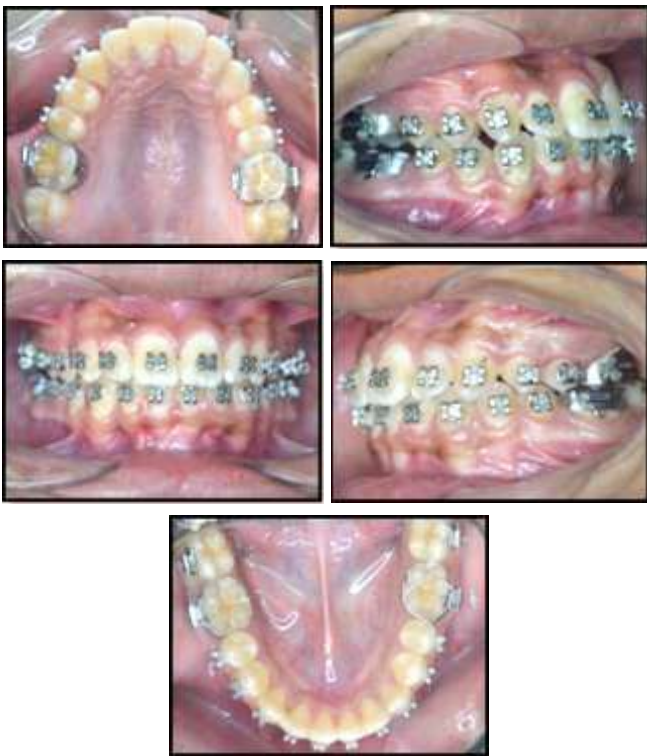

Fig. 7 Post treatment intraoral photograph

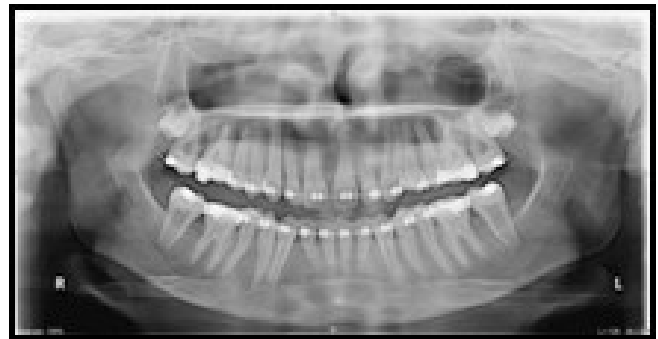
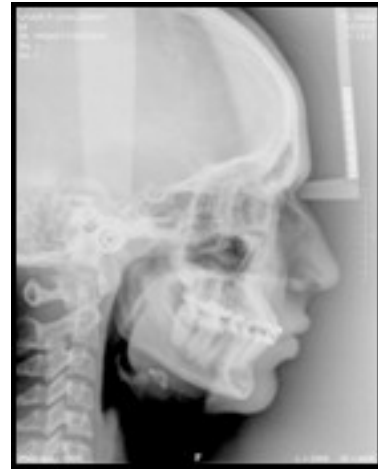

Fig. 8 Post treatment Radiographs

**RESULT:-**

Table 1. case analysis	Pre treatment	Post treatment
SNA	76°	75°
SNB	72°	74°
ANB	4°	1°
FMA	69°	72°
SN GO GN	29°	30°
<b>Upper incisor</b>		
To NA	6 mm	9 mm
<b>Lower incisor</b>		
To NB	4 mm	7 mm

Normal functional occlusion was established with normal anterior overbite and overjet. Distalization and intrusion of maxillary posteriors and forward placement of lower teeth and Proclination of lower anterior. The mandibular asymmetric retrognathism was eliminated, the patient's facial asymmetry was much improved with harmony of dental arch and orofacial functions.

## Discussion:-

Class II malocclusions resulting from mandibular retrusion are generally treated with functional orthodontic appliances that create orthopedic forces directed at the mandibular structures. These appliances influence the jaws via the following mechanisms: remodelling of the mandibular condyle, remodelling of the glenoid fossa, repositioning the mandibular condyle in the glenoid fossa, and autorotation of the mandibular bone.

Functional appliances are valuable means of correcting sagittal discrepancies caused by retrognathic or repositioned mandible. In recent years, the use of fixed functional appliances has been increasing specially in noncompliant patient. These appliances also help to integrate the functional and fixed phases of treatment into a single phase treatment. The overall treatment duration is therefore reduced. So fixed functional appliances are boon for orthodontist faced with non-compliance having mandibular retrognathia.

The Forsus Fatigue-Resistant Device (FRD) is persuasive because it is capable of achieving class II correction in 3 to 6 months depending upon the baseline situation and the biological response. The correction achieved is by a combination of skeletal and dental effects, 66% being dental and remaining 34% skeletal.

thus, Forsus FRD offers the following advantages to the clinician:-

1. Predictable results.
2. Long term reliability.
3. Can be used in non-compliant or handicapped patients.
4. Ease of installation (can be installed and removed in 5 minutes, and is activated in 30 seconds)

5. Less breakages and robust in clinical usage.
6. Shortens the duration of treatment.
7. Can make use of residual growth even beyond the pubertal growth spurt.
8. Susceptibility to mechanical fatigue is negligible due to the spring.

## For patients

1. It allows freedom of jaw movements.
2. No tissue impingement.

The dilemma today for any thinking orthodontist how to achieve objective with each guru offering orthodontics heaven if proper technique and appliance are used.

## CONCLUSION:-

The fixed functional appliance deals with the variety of class II malocclusion which represents gamut of challenges the clinician faces.

Hence, it is concluded that most class II situations are on account of a functional retrusion of the mandible. It would be very unwise to consider extractions in such situations. They are best managed by a non-extraction approach of mandibular advancement wherein Forsus FRD is the treatment of choice, especially for non-compliant patients with stable result.

## BIBLIOGRAPHY:-

1. Ritoo A.K, Ferreira A p. fixed functional appliances-classification functional orthod 2000; 17: 12-30,32.
2. Nelson B, Hansen K, Hagg U. Class II correction in patients treated with class II elastics and with fixed functional appliances: a comparative

study. Am J Orthod Dentofacial Orthop.2000;118:142–149.

3. Nina Heinig, Gernot R. Goz. Clinical Application and Effects of the Forsus TM Spring–A Study of New Herbst Hybrid. Journal of Orofacial Orthopedics.2001;6:436–450.

4. A KorrodiRitt. Fixed Functional Appliances – A Classification (Updated). Orthodontic Cyber Journal.

5. William Vogt. The Forsus Fatigue Resistant Device. Journal of Clinical Orthod. June 2006;11:368-77.

6. Dennis G. Dionne. Clinical Trial Report: ForsusTM Fatigue Resistant Device. Orthodontic Perspectives – Winning Combinations. 2002;IX: 11-12