

# Compound Odontoma Clinically Presenting As A Supernumerary Tooth – A Rare Case Report

## A Case Report

\*Sanyal Shah, \*\*Bhavin Dudhia, \*\*\*M Kamil Mansuri, \*\*\*\*Yesha Jani, \*\*\*\*\*Purv Patel

### ABSTRACT

Odontomas are the most common type of odontogenic tumours. They are considered as hamartomas rather than true neoplasms. They are primarily composed of enamel, dentin, cementum and pulp. They are classified as complex odontoma and compound odontoma. A malformation in which all dental tissues formed in less orderly pattern is complex odontoma. A malformation in which all dental tissues are arranged in a more orderly pattern than complex odontoma is compound odontoma. Odontomas are generally asymptomatic and may appear as small, solitary or multiple radio-opaque lesions on routine radiographic examinations. Occasionally, they may cause disturbances in the eruption of teeth such as impaction, delayed eruption or retention of primary teeth. In exceptional cases, they erupt in the oral cavity. This is a rare case report of a compound odontoma in a 20 year old female, which presented clinically as a supernumerary tooth.

**Keywords:** compound odontoma, supernumerary teeth, hamartoma

**Received:** 28-07-2014; **Review Completed:** 17-08-2014; **Accepted:** 15-10-2014

### INTRODUCTION:

An odontoma is a mixed-tissue benign lesion of odontogenic origin exhibiting complete dental tissue differentiation.<sup>1</sup> Constituting 22% of all odontogenic tumours, they lack proliferation potential.<sup>2</sup> Rather than true neoplasms, odontomas are probably a hamartomatous malformation of functional ameloblasts and odontoblasts consisting of enamel, dentin, cementum and pulp.<sup>1</sup>

Classification by World Health Organization (WHO):<sup>3</sup>

1. Complex odontoma: A malformation in which all the dental tissues are well formed, but occurring in a less orderly pattern.

2. Compound odontoma: A malformation in which all the dental tissues are arranged in a more orderly pattern than in the complex odontoma, so that the lesion consists of many tooth-like structures.<sup>3</sup>

The etiology of odontoma has been attributed to local trauma, inflammatory and/or infectious processes, hereditary anomalies (Gardner's syndrome, Hermann's syndrome, Basal cell nevus

syndrome), odontoblastic hyperactivity, alterations in genetic component and persistence of a portion of lamina.<sup>1,2,4</sup>

Epidemiologically, odontomas account for 22–67% of all maxillary tumours.<sup>5</sup> The majority of odontomas located in the anterior region of the maxilla are compound, while those in the posterior areas, especially in the mandible, are complex odontomas.<sup>6</sup> Odontomas occur more often in the permanent dentition and rarely associated with the primary teeth.<sup>1,4</sup>

An increased prevalence of these tumours can be found in children and adolescents.<sup>5</sup> There is no gender predilection and most lesions are detected on routine radiographs.<sup>7</sup> The canines, followed by upper central incisors and third molars, are the most frequent teeth impacted by odontomas.<sup>8</sup>

The mechanism of odontoma eruption appears to be different from tooth eruption because of lack of the periodontal ligament in odontoma. Therefore, the force required to move the odontoma is not linked to the contractility of fibroblasts, as is the case for the

\* Reader, \*\* Professor and Head, \*\*\* Post Graduate Student, \*\*\*\*Senior Lecturer, \*\*\*\*\*Senior Lecturer

DEPARTMENT OF ORAL MEDICINE AND RADIOLOGY AHMEDABAD DENTAL COLLEGE AND HOSPITAL, TA. KALOL, DIST. GANDHINAGAR GUJARAT, INDIA.

ADDRESS FOR AUTHOR CORROSPONDENCE : DR. MKAMIL MANSURI, TEL: +91 8401668309

teeth. Although there is no root formation in odontoma, its increasing size may lead to the sequestration of the overlying bone and, hence, occlusal movement or eruption. An increase in size of the odontoma over time produces a force sufficient to cause bone resorption. Another reason for odontoma eruption could be the bony remodelling of the jaws.<sup>9</sup>

Odontomas are asymptomatic, have slow growth, and seldom exceed the size of a tooth, but when enlarged can cause expansion of the cortical bone.<sup>3,7,10</sup> They may cause disturbances in the eruption of teeth, such as impaction, delayed eruption or retention of primary teeth, esthetically unsatisfactory dental appearance, with features of spacing, labial or palatal displacement of the permanent tooth as a result of an abnormal path of eruption, and presence of other malocclusion traits in the patients.<sup>11</sup> This could also be associated with functional impairment and emotional disturbance in the individual.<sup>8</sup>

Radiographically, they generally appear as small, solitary or multiple radio-opaque lesions. Complex odontoma appears as an irregular mass of calcified material surrounded by a thin radiolucent area with smooth periphery, and the compound type shows calcified structures resembling teeth in the centre of a well-defined radiolucent lesion.<sup>8</sup> Surgical removal is the treatment of choice for odontomas, with no possibility of recurrence, if the lining epithelium is removed intact.<sup>9</sup> Care should be taken, however, not to harm adjacent permanent teeth and germs in children.<sup>6</sup>

Histopathological examination of compound odontomas shows tooth-like structures which resemble pulp tissue in the central portion surrounded by a dentin shell and partially covered by enamel.<sup>8</sup> Complex odontomas are conglomerates

without orientation of dentin, enamel, enamel matrix, cementum and areas of pulp tissue.<sup>12</sup>

The present case describes a patient with compound odontoma erupted into the oral cavity resembling a supernumerary tooth.

## CASE REPORT

A 20 year old female patient reported to dental out-patient-department with the chief complaint of extra tooth in the lower left back region of jaw since last two years. Patient was relatively asymptomatic before two years. Then she noticed an extra tooth in same region.

On intraoral examination, an extra tooth-like structure resembling a premolar was present lingual to 34 (Figure-1).

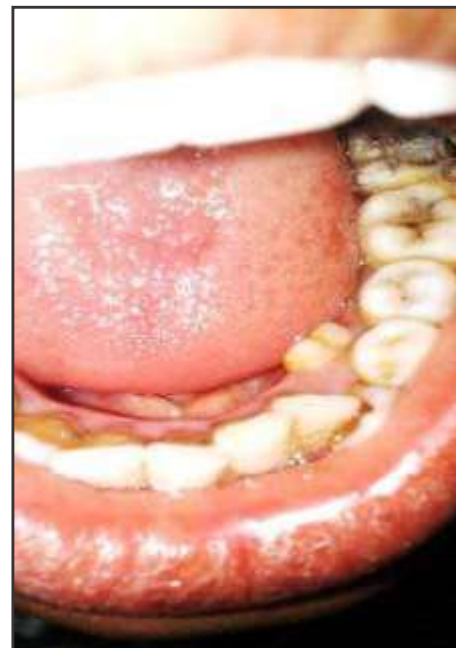

Figure 1: Clinical photograph showing erupted compound odontoma clinically seen as supernumerary teeth lingual to lower left premolar

On palpation, extra tooth-like structure was hard and non-mobile. There was no associated erythema, ulceration or pain in the surrounding the mucosa 33 was displaced labially with mild crowding of teeth in mandibular anterior region. Based on these

findings, clinical diagnosis of supernumerary tooth in 34 region was placed.

An intraoral periapical radiograph was advised to determine the extent and relation of the supernumerary tooth to surrounding structures. It showed a single radiopaque tooth like structure present in relation to 33 and 34, with well defined smooth periphery (Figure-2).

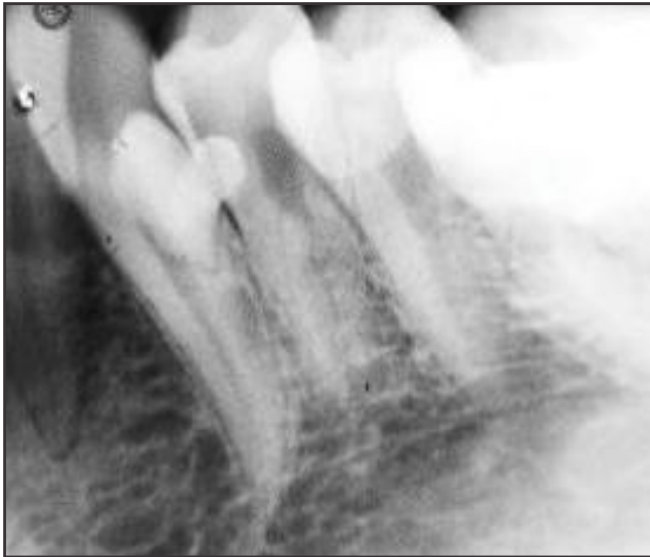

Figure 2: Intraoral periapical radiograph showing radiopaque tooth like single structure with radiolucent halo inside the opacity

The internal structure was densely radiopaque, with coronal resemblance to premolar-like cusp tips without root formation.

The tooth-like structure was surgically removed under local anesthesia. Gross examination of the specimen showed tooth like structure with no evidence of root structure (Figure-3).

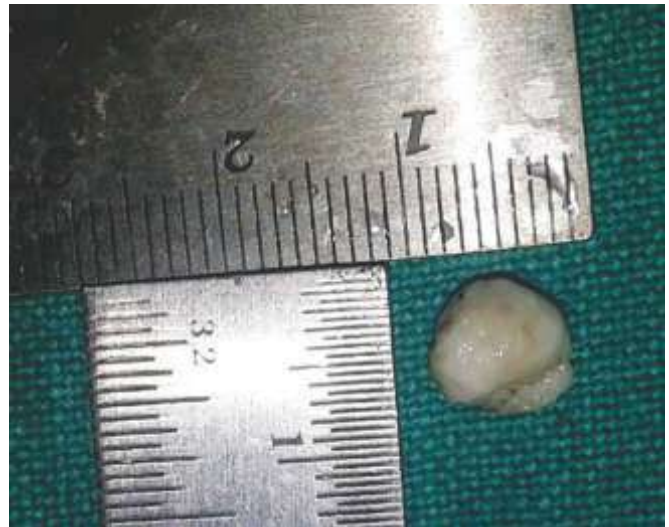

Figure 3: An extracted specimen of erupted compound odontoma consisting of tooth like structure with no evidence of root structure.

Correlating radiographic feature with removed surgical specimen, differential diagnosis of odontoma was kept and the specimen was sent to oral pathology department for histopathologic examination.

The histopathology showed enamel, dentin and pulpal tissue arranged in orderly pattern with surrounding fibrous connective tissue containing spherical calcifications and odontogenic rest which confirmed the diagnosis a compound odontoma [Figure 4 (a) and (b)]. Healing of the socket was uneventful. Patient was advised further treatment for the malaligned anterior tooth.

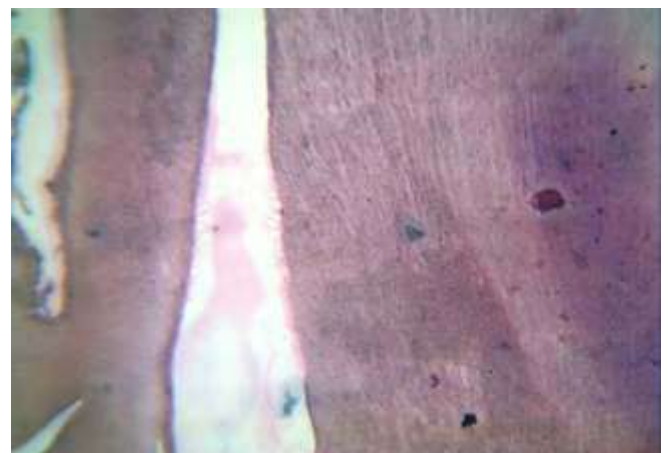
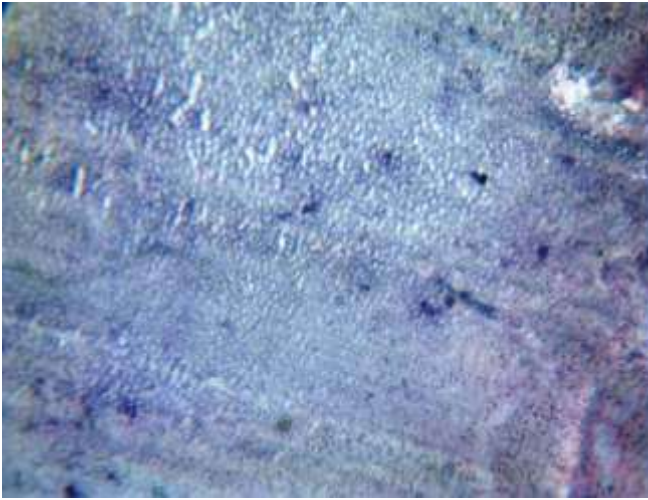


Figure 4(a)



**Figure 4(b)**

Figure 4 (a) Microphotograph at 10x and (b) Microphotograph at 40x. showing enamel, dentin and pulpal tissue arranged in orderly pattern. Surrounding fibrous connective tissue contain spherical calcifications and odontogenic rests.

## DISCUSSION

Odontogenic tumors are rare jaw lesions that affect less than 1% of the population. They represent an attempt to duplicate tooth formation, but in a distorted fashion.<sup>4</sup> Paul Broca was the first person who coined the name 'Odontoma' in 1867. Broca defined the term as tumours formed by the overgrowth or transitory of complete dental tissue. Howards had listed odontoma as fourth category of supernumerary teeth.<sup>13</sup>

Clinically, three types of odontomas are recognized in the literature: intraosseous (central), extraosseous (peripheral) and erupted odontomas. The intraosseous odontoma occurs inside the bone and may erupt into the oral cavity. The extraosseous odontoma occurs in the soft tissue.<sup>13</sup> Pain and swelling are the most common symptoms when odontomas erupt, followed by malocclusion. Recurrent infection following the eruption into the oral cavity has been reported.<sup>9</sup>

Radiographically, odontoma presents as a well defined radiopacity situated in bone but with a density greater than bone and equal to or greater than that of a tooth. It contains foci of variable density. It is present with a radiolucent halo, typically surrounded by a thin sclerotic line, surrounding the radiolucency. Radiolucent zone is the connective tissue capsule of a normal tooth follicle. Thin sclerotic line resembles the corticated border seen in a normal tooth crypt. Developmental stages can be identified based on radiologic features and the degree of calcification of the lesion at the time of diagnosis. First stage is characterized by radiolucency due to the absence of dental tissue calcification, the second or intermediate stage shows partial calcification and the third or classically radiopaque stage exhibits predominant tissue calcification with a surrounding radiolucent halo.<sup>9</sup>

Odontomas erupting into the oral cavity are extremely uncommon, with the first case being reported by Rumel et al in 1980. In 2009, Serra-Serra et al reported that, since 1980 only 17 cases of erupted odontomas were documented in the literature, and including their three patients, it would be 20 cases in the literature. Of the 20 reported cases of erupted odontomas, nine correspond to compound odontomas and 11 to complex odontomas.<sup>14</sup>

However, the mechanism behind eruption time remains uncertain as some odontomas erupt at a young age and others at an older age. Eruption of odontomas are most often seen in older people. Thus, it is likely that resorption of the edentulous part of the alveolar process plays a role, but it is also possible that reactive growth of the capsule contributes to this phenomenon. Eruption at a young age is possible through bone remodelling that might have resulted from the presence of dental

follicles.<sup>9</sup>

This case needs to be differentiated from supernumerary teeth. Supernumerary tooth (ST) is a developmental anomaly and had been argued to arise from multiple etiologies. These teeth may remain embedded in the alveolar bone or can erupt into the oral cavity. The erupted supernumerary tooth might cause aesthetic and/or functional problems.<sup>15</sup> In the primary dentition, the prevalence is said to be 0.3%-0.8% and in the permanent dentition 1.5%-3.5%.<sup>15</sup> Supernumeraries can be impacted, erupt spontaneously, or exhibit ectopic eruption. These teeth located especially in the premaxilla can cause certain clinical problems such as failure to erupt, displacement of a permanent tooth, crowding, or dentigerous cyst formation.<sup>16</sup> They are more commonly seen in males. Supernumerary teeth are of two types—supplemental and rudimentary. Supplemental tooth is the one that resembles a normal tooth both morphologically and histopathologically and is located adjacent to the normal tooth; whereas a rudimentary type tooth is a tooth like structure of variable size and shape. However, histopathologically both types represent the normal organization of the tooth structure, such as enamel, dentin, pulp and cementum including the periodontal ligament.<sup>9</sup>

In our case, radiographically it appeared as a single

radiopaque tooth like structure with well defined smooth periphery and densely radiopaque internal structure, with coronal resemblance to cusp tips and no root like structure beneath it, which differentiated it from supernumerary tooth.

Since odontomas are well encapsulated lesions and have less chances of recurrence, the management comprises of conservative surgical enucleation.<sup>17</sup> In the current case, surgical excision of the compound odontoma was performed.

## CONCLUSION

In conclusion, this paper describes a rare case of asymptomatic erupted compound odontoma causing only mild crowding of anterior teeth. Most often such cases are diagnosed as supplemental or supernumerary tooth. Since odontomas represent a large proportion of jaw tumours, adequate knowledge of their characteristics is necessary for establishment of proper diagnosis and management. An early diagnosis and management of odontomas are essential to prevent later complications, such as failure of eruption of the primary and permanent teeth.

## REFERENCES:

1. Maden AE.A Case Report of Compound Odontoma Associated with an Unerupted Maxillary Central Incisor. Arch ClinExpSurg2014; 3(1):47–51.
2. Tejasvi ML, Balaji BB. Erupted Compound Odontomas: A Case Report. Journal of Dental Research, Dental Clinics, Dental Prospects2011; 5(1).
3. Prabhakar C, Haldavnekar S, Hegde S. Compound- Complex odontoma- An important clinical entity.J. Int Oral Health 2012; 4(1).
4. John B, John R, elango I. Compound Odontoma Associated with Maxillary Primary Tooth – A Case Report. JIADS 2010; 1(1).
5. Salgado H, Mesquita P. Clinical case Compound odontoma—Case report. rev port

- estomatol med dent cirmaxilofac 2013;54(3): p. 161–165.
6. Iatrou I, Vardas E, Theologie-LygidakisN, Leventis M. A retrospective analysis of the characteristics, treatment and follow-up of 26 odontomas in Greek children. *Journal of Oral Science* 2010;52(3): p.439-447.
  7. Brenda LN, Nelson L, Lester DR. Compound Odontoma. *Head and Neck Pathol* 2010
  8. De Oliveira BH, Vera Campos MS, Marçal MS. Compound odontoma – diagnosis and treatment: three case reports. *American Academy of Pediatric Dentistry* 2001; 23: 2.
  9. Nadendla LK. Erupted compound odontoma: Report of a rare case. *Journal of Oral and Maxillofacial Radiology* 2013; 1(2).
  10. Gabriel S, BA Leonardo BA, Cosme GE. Erupted odontomas: A report of three cases and review of the literature. *Med Oral Pathol Oral Cir Bucal* 2009;14(6): p. 299 - 303.
  11. Lee CH, Park GJ. Complex and compound odontomas are clinico-pathological entities. *Basic and Applied Pathology* 2008; 1: p. 30–33.
  12. Andrade Santos PP, Amorim Barroso KM, De Souza LB, Da Costa MM. Odontomas: Clinicopathologic study of 104 cases and a case report of compound odontoma associated in an unerupted maxillary central incisor in a child. *International dentistry – african edition*; 2(5).
  13. Krichen G, Hentati H, Hadhri R, Zakhama A, Selmi J. Case report: Odontoma associated with supernumerary and Impacted teeth. *International Dental Journal Of Student's Research* 2013; 1(4).
  14. Patil S, Maheshwari S. Erupted Compound Odontoma: Report of a Rare Case and Literature. Update. *Universal Research Journal of Dentistry* 2013;3(3)15. Fazliah SN. Supernumerary tooth : report of a rare case. *Archives of Orofacial Sciences* 2007;2. P. 54-58
  16. ElcinE, OzgurMS, OnurAA, TuncerO, Ceyhan A, Feridun B. Supernumerary teeth in a Turkish population. *American Journal of Orthodontics and Dentofacial Orthopedics* 2009; 136(6).
  17. Patil S, Kaswan TS. Erupted odontomas: a report of two unusual cases. *RSBO* 2012;9(2):199-203.