

*Zalak A. Sharma, **Devavrat H. Patel, ***Shilpi Shah, ****Archita Kikani

ABSTRACT

The goal of crown lengthening is to provide a tooth crown dimension adequate for a stable dentogingival complex and for the placement of a restorative margin, so as to achieve the best marginal seal and an aesthetically pleasing final restoration. The esthetic crown lengthening requires gingivectomy procedures to expose the needed additional tooth structure; therefore, a minimum of 2 to 5 mm of keratinized tissue is necessary to ensure the gingival health. This present case report the installation of definitive prosthesis was carried out after the healing period of the gingiva, in order to obtain the aesthetic position of the prosthetic margin.

Key Report: Keratinized attached gingiva, Biologic width, Internal Bevel Incision Crown Lengthening Procedure

INTRODUCTION:

Crown lengthening is a surgical procedure designed to increase the extent of supragingival tooth structure for restorative or esthetic purposes by apically positioning the gingival margin, removing supporting bone or both.¹

Various Indications for crown lengthening Procedure are teeth with subgingival caries or extensive caries that shortens the tooth, fractures, and short clinical crowns caused by incomplete exposure of the anatomic crowns. And several techniques such as gingivectomy, undisplaced flap with or without osseous surgery, apically repositioned flap with or without resective osseous surgery, and orthodontic forced eruption with or without fibrotomy have been proposed for clinical crown lengthening. But to decide the type of technique biologic width plays a very important role.

Biologic width is defined as the physiologic dimension of the junctional epithelium and connective tissue attachment, according to the pioneering study conducted by Gargiulo et al.² In this study, the authors demonstrated that humans, in average, show a connective tissue attachment of 1.07 mm, above the alveolar bone crest, and a junctional epithelium, below the base of the gingival sulcus, of 0.97 mm. The combination of these two measurements constitutes the biologic width, that is, 2.04 mm in average. Ingber et al. suggested that an additional 1 mm might be coronally added to the 2 mm dentogingival junction, as an optimal distance between the bone

crest and the margin of a restoration, to permit healing and proper restoration of the tooth.³ In addition, during an esthetic crown lengthening procedure, bone removal plays an important role in the final location of the free gingival margin after healing.

The ultimate goal of crown lengthening is to provide a tooth crown dimension adequate for a stable dentogingival complex and for the placement of a restorative margin, so as to achieve the best marginal seal and an aesthetically pleasing final restoration.⁴

In this case report we aim to describe the surgical sequence of crown lengthening to apically reposition the dentogingival complex, in addition to an esthetic restorative procedure.

CASE REPORT

A 61 year – old male patient with a non-contributory medical history, with no history of smoking and alcohol consumption presented to Department of Periodontics at Ahmedabad Dental hospital with short clinical crowns and diastema(**Fig-1**). On extraoral examination there were no significant findings with normal lip line and minimal gingival display while smiling. On dental examination revealed that his 11,12,13,14,15,21 treated endodontically. The Periodontal examination revealed good oral hygiene with minimal plaque and calculus deposits. The gingiva was pink and firm, and papillae were intact. On clinical examination revealed shallow probing depths of 1.5 – 2.5 mm in all teeth with no mobility and 5 mm of

* PG Student, **PG Student, ***Professor & Head, ****Professor

DEPARTMENT OF PERIODONTICS AND ORAL IMPLANTOLOGY
AHMEDABAD DENTAL COLLEGE AND HOSPITAL TA. KALOL, DIST: GANDHINAGAR, GUJARAT, INDIA.

ADDRESS FOR AUTHOR CORROSPONDENCE : DR. ZALAK A. SHARMA, E-mail : sharmazalak788@gmail.com Ph: +91 8140172233

keratinized attached gingiva along with crown to root ratio 1:3 (Fig 3). Radiographic examination shows 11,12,13,14,15,21 with root canal fillings with minimal interdental bone loss and roots were found to be of adequate length (Fig-2). As the patient wants to undergo full mouth rehabilitation and better esthetics , crown lengthening procedure recommended to increase the extent of supragingival tooth structure and to allow a healthy, optimal relationship between restoration and periodontium. Patient was informed thoroughly the Pros & Cons of surgical technique. Initially, an impression of the maxilla was obtained to prepare a surgical guide in silicon. (Fig- 10)After giving local anesthesia (lidocaine 2%) , transgingival probing was done around the intended teeth and found that 2-2.5 mm of soft tissue present above the alveolar crest(Fig-4-Fig-9). After inserting guide in mouth and the new gingival margin was registered with a No. 15 Bard-Parker blade(Fig-11). Initial internal level

incision was performed 3 mm apical to the gingival margin so as to achieve the scalloped contour both on labial and palatal aspect(Fig-12 & Fig-13). As there was sufficient amount of attached gingiva (5 mm) present, to give a remaining 2 mm around the restoration, so the procedure most suitable was crown lengthening followed by resective osseous procedure. Hence a full thickness mucoperiosteal flap was raised(Fig-14). Osseous resection was performed using low speed handpiece and carbide bur under copious saline irrigation to maintain the biologic width . The flap was repositioned and sutured(Fig-15) .Chlorhexidine rinse 0.2% bid was prescribed for 2 weeks, and the patient was given appropriate postoperative instructions. After one week , suture removal is done and good healing observed with increase in crown-root ratio(Fig-16 & Fig-17). After 3 months follow-up temporary prosthesis given(Fig-18).

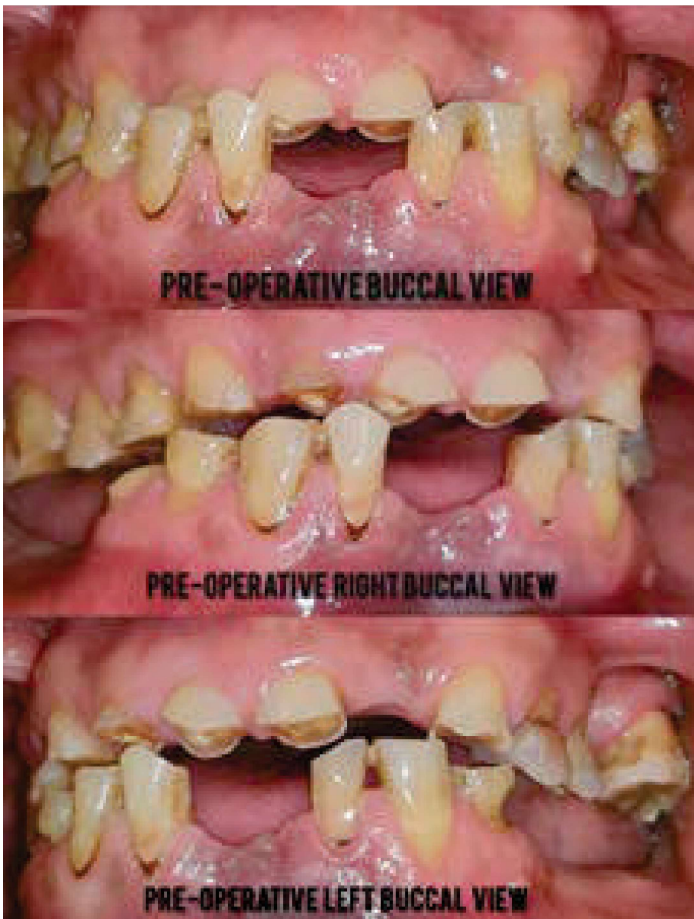


FIG-1 - Pre-Operative View

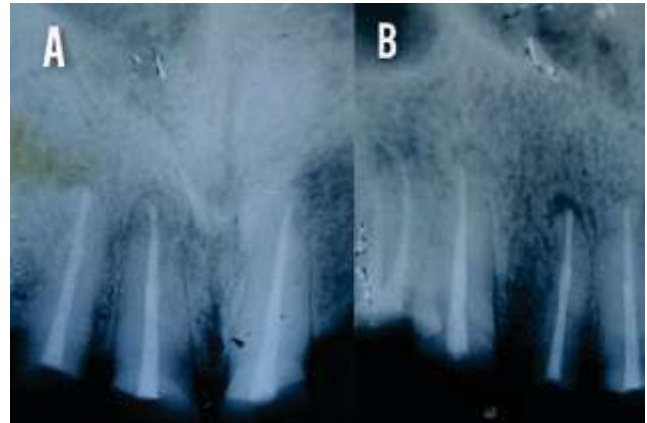


FIG-2 A: Endodontically treated 11,12 & 21
B: Endodontically treated 13,14,15

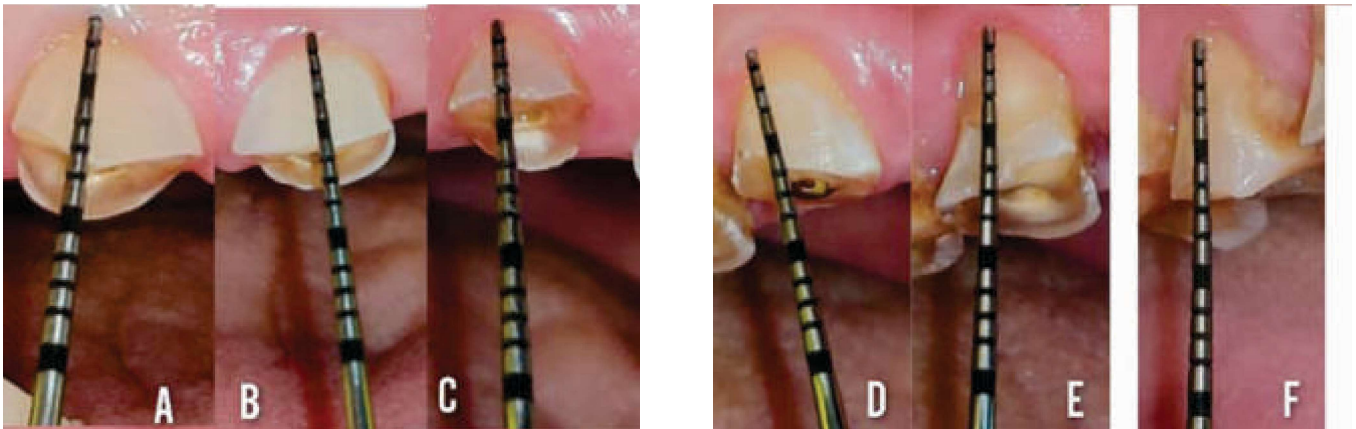


FIG-3-PRE- OPERATIVE

**A: Crown length irt 11 is 6mm
B: Crown length irt 21 is 5.5mm
C: Crown length irt 12 is 3 mm**

**D: Crown length irt 13 is 5mm
E: Crown length irt 14 is 6 mm
F: Crown length irt 15 is 6 mm**

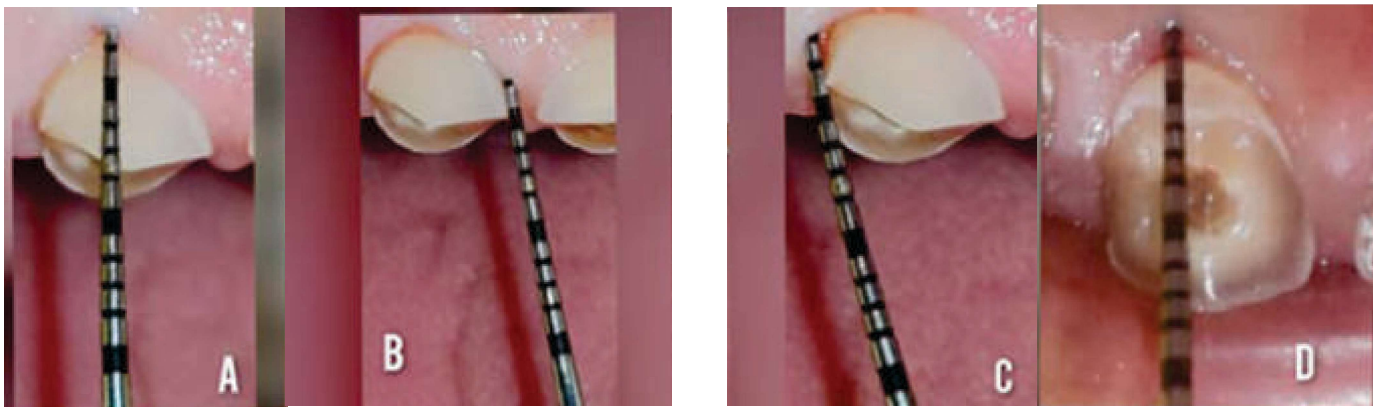


FIG-4

**A: Biologic width on Mid-Buccal irt 11 is 2.5mm
B: Biologic width on Mesio- Buccal irt 11 is 2.5mm**

**C: Biologic width on Disto-Buccal irt 11 is 1.5mm
D: Biologic width on Mid-Palatal irt 11 is 2 mm**

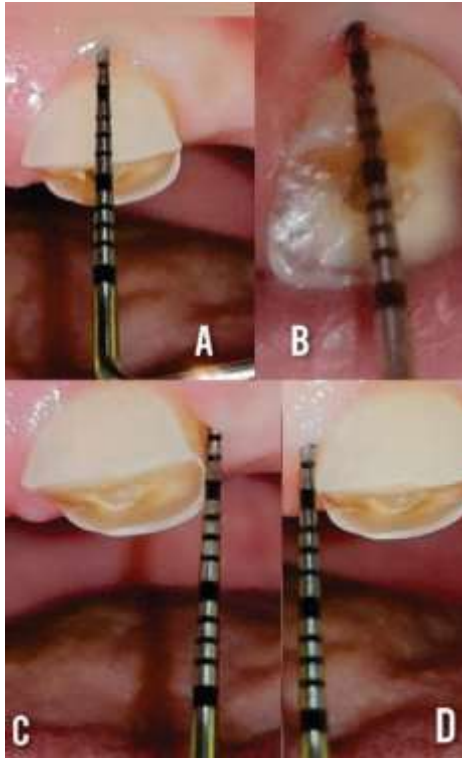


FIG:5
A: Biologic width on Mid-Buccal irt 21 is 1.5mm
B: Biologic width on Mid-Palatal irt 21 is 3mm
C: Biologic width on Disto-Buccal irt 21 is 2mm
D: Biologic width on Mesio-Buccal irt 21 is 2mm

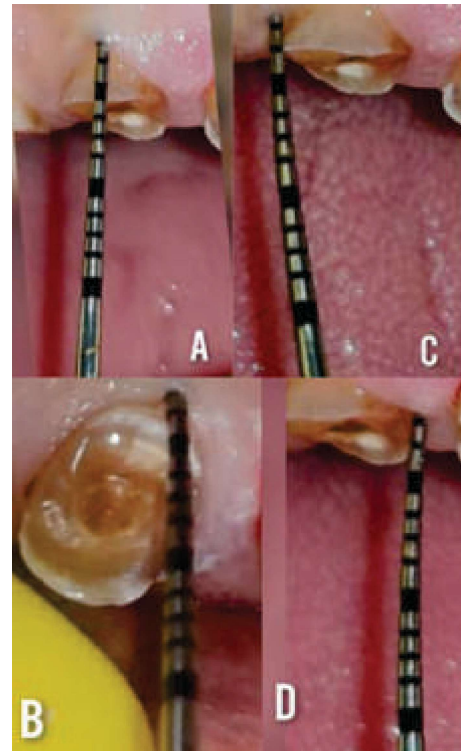


FIG:6
A: Biologic width on Mid-Buccal irt 12 is 1.5 mm
B: Biologic width on Mid-Palatal irt 12 is 2 mm
C: Biologic width on Disto-Buccal irt 12 is 1.5 mm
D: Biologic width on Mesio-Buccal irt 12 is 2 mm

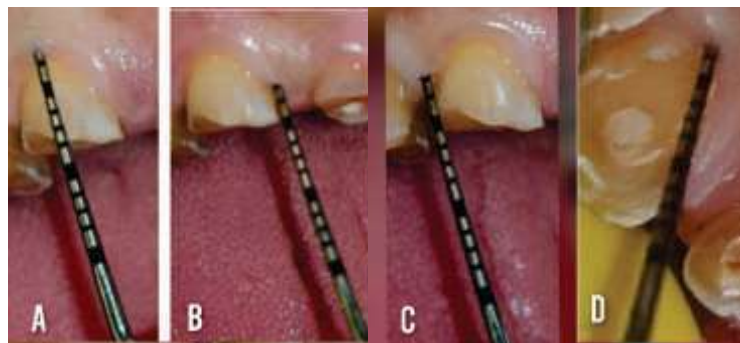


FIG:7
A: Biologic width on Mid-Buccal irt 13 is 2.5mm
B: Biologic width on Mesio-Buccal irt 13 is 2 mm
C: Biologic width on Disto-Buccal irt 13 is 2 mm
D: Biologic width on Mid-Palatal irt 13 is 2.5mm

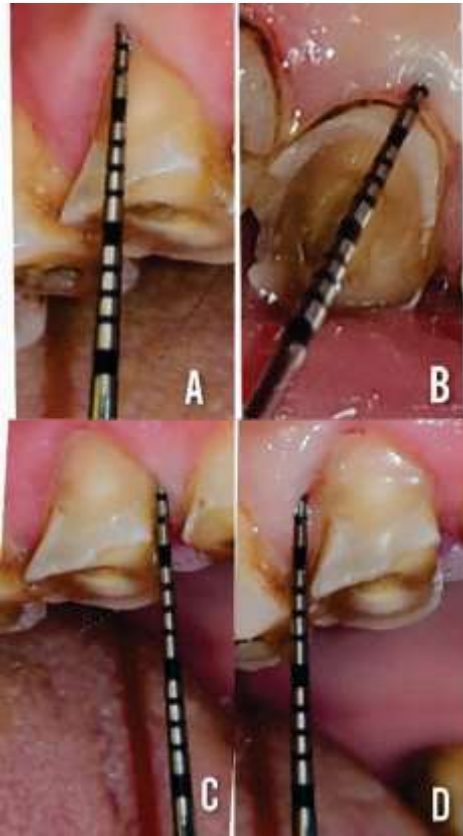


FIG:8

- A: Biologic width on Mid-Buccal irt
14 is 1.5mm**
- B: Biologic width on Mid-Palatal irt
14 is 2mm**
- C: Biologic width on Mesio-Buccal irt
14 is 2mm**
- D: Biologic width on Mesio-Distal irt
14 is 2mm**

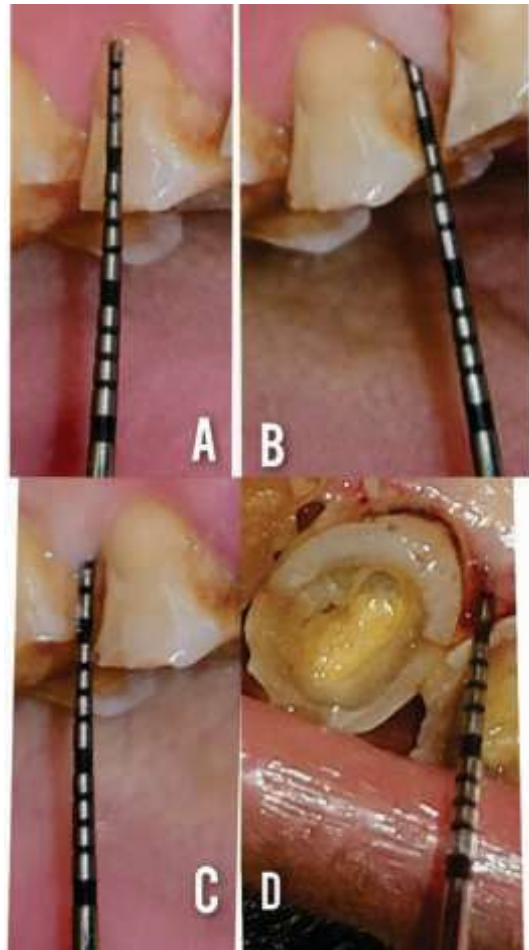


FIG:9

- A: Biologic width on Mid-Buccal irt
15 is 1mm**
- B: Biologic width on Mesio-Buccal irt
15 is 2mm**
- C: Biologic width on Disto-Buccal irt
15 is 2mm**
- D: Biologic width on Mid-Palatal irt
15 is 3mm**

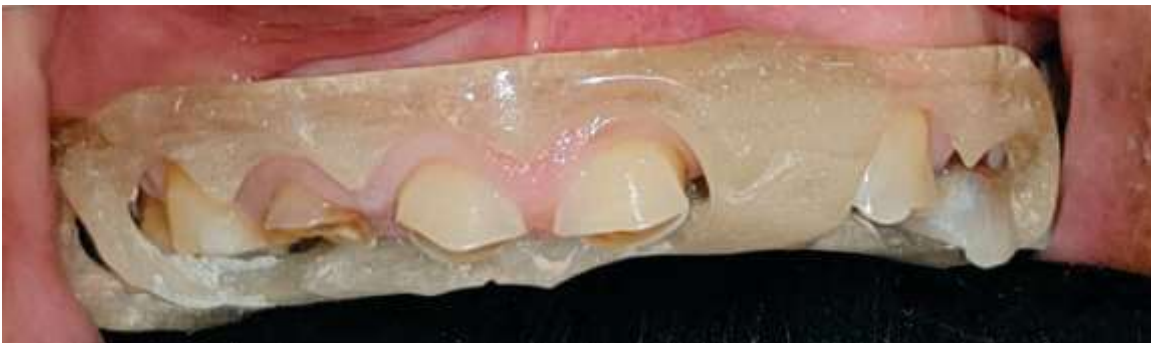

FIG:10 Surgical guide is placed

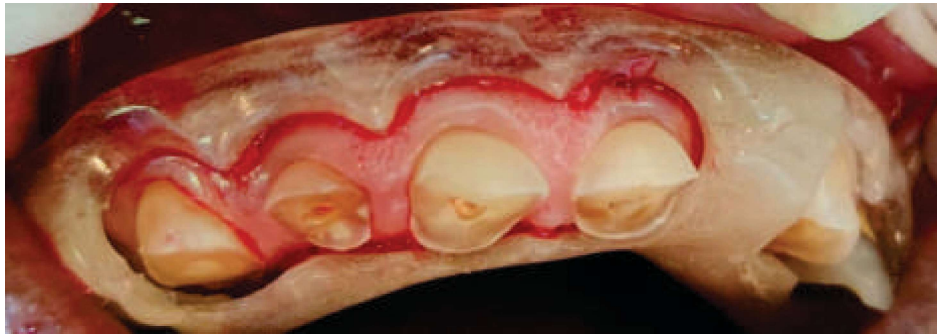

FIG:11 After inserting guide in and the new gingival margin was registered with a No. 15 Bard-Parker blade

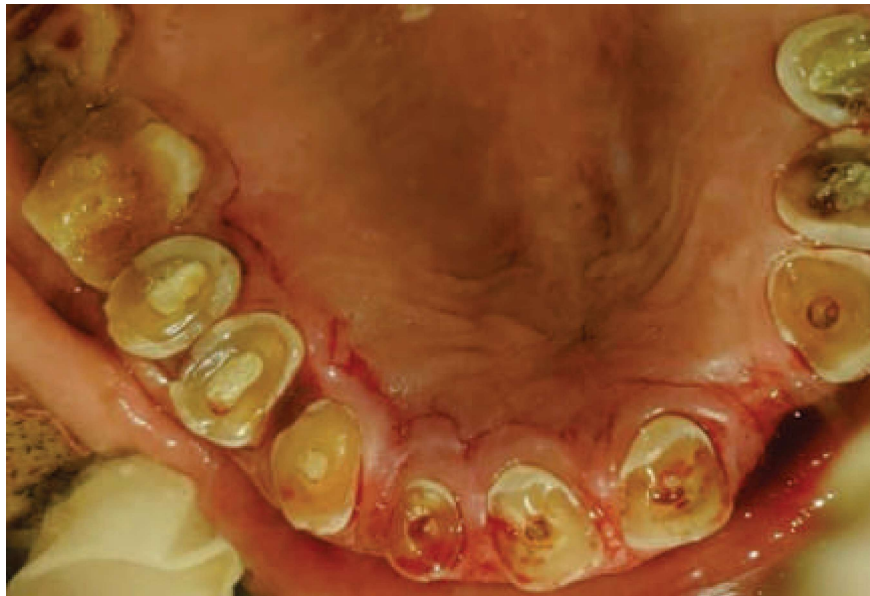

FIG:12 Internal Bevel Incision is given



FIG:13- Excised Tissue

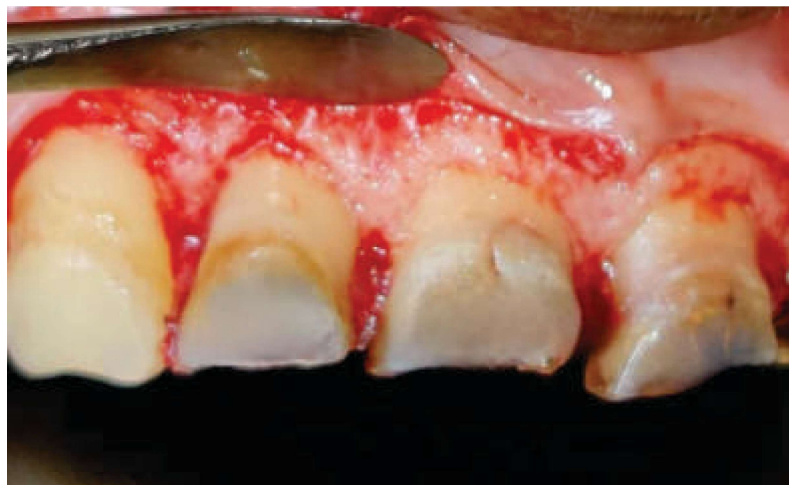

FIG:14 Reflection of Flap irt 11,12,13,14 & Bone trimming is done

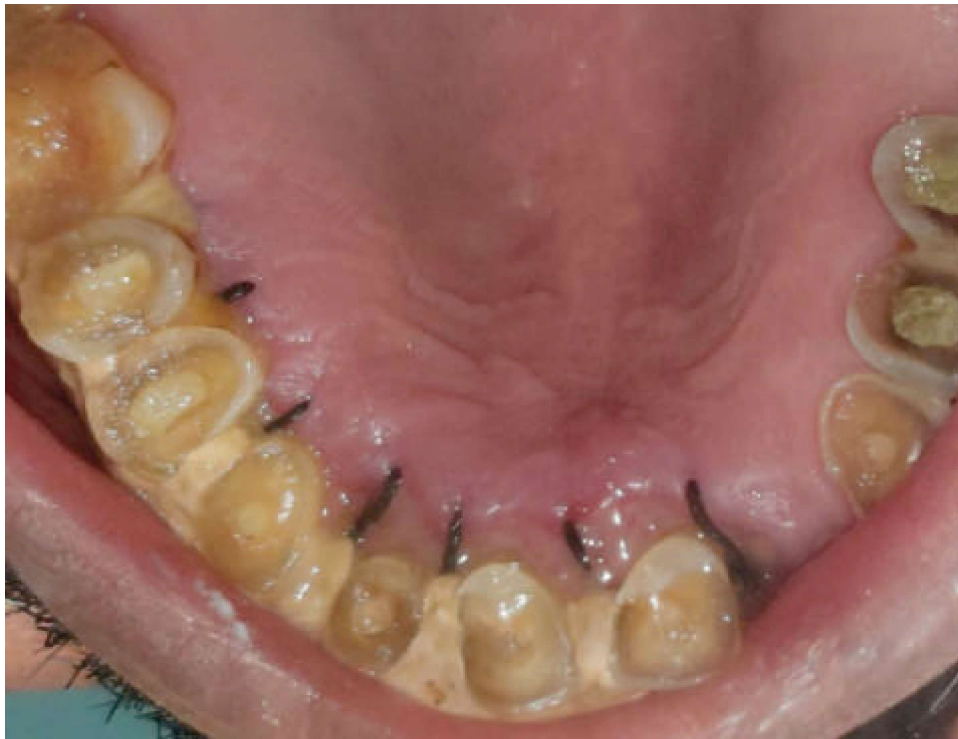
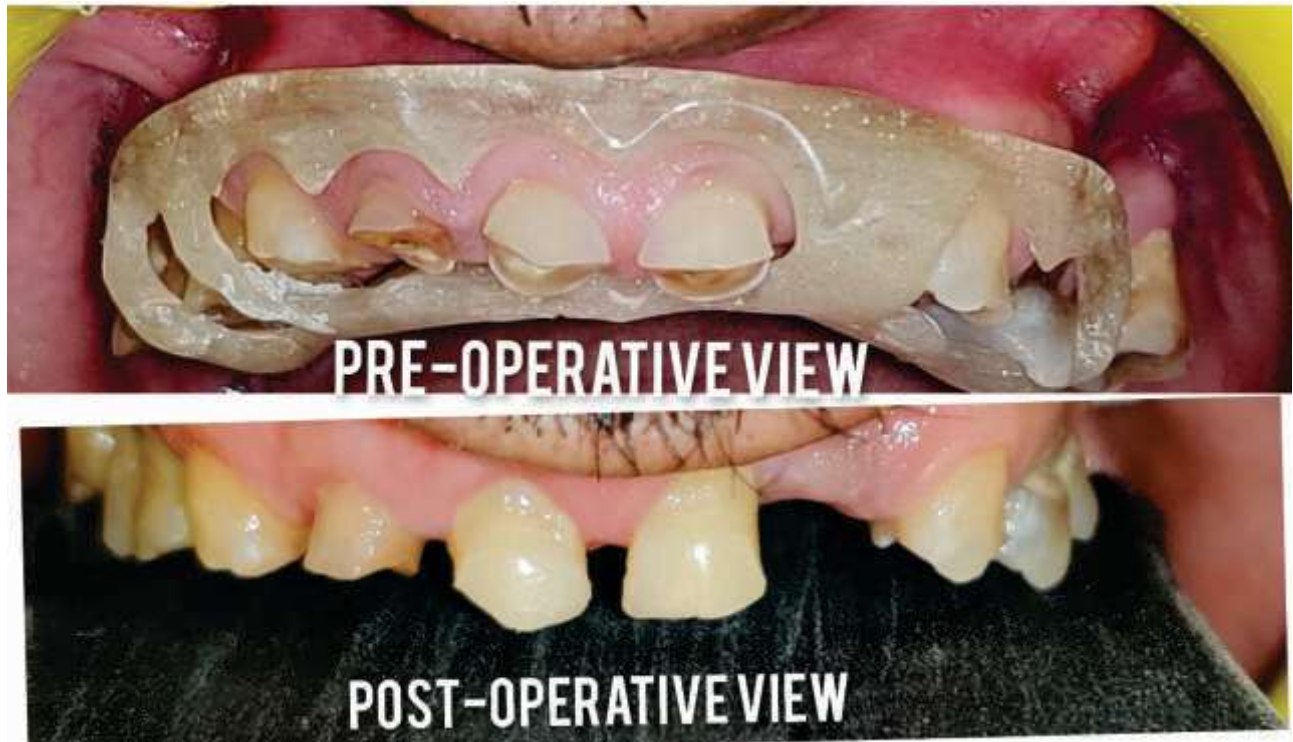
FIG:15 - Sutures in Place irt 11,12,13,14,15,21



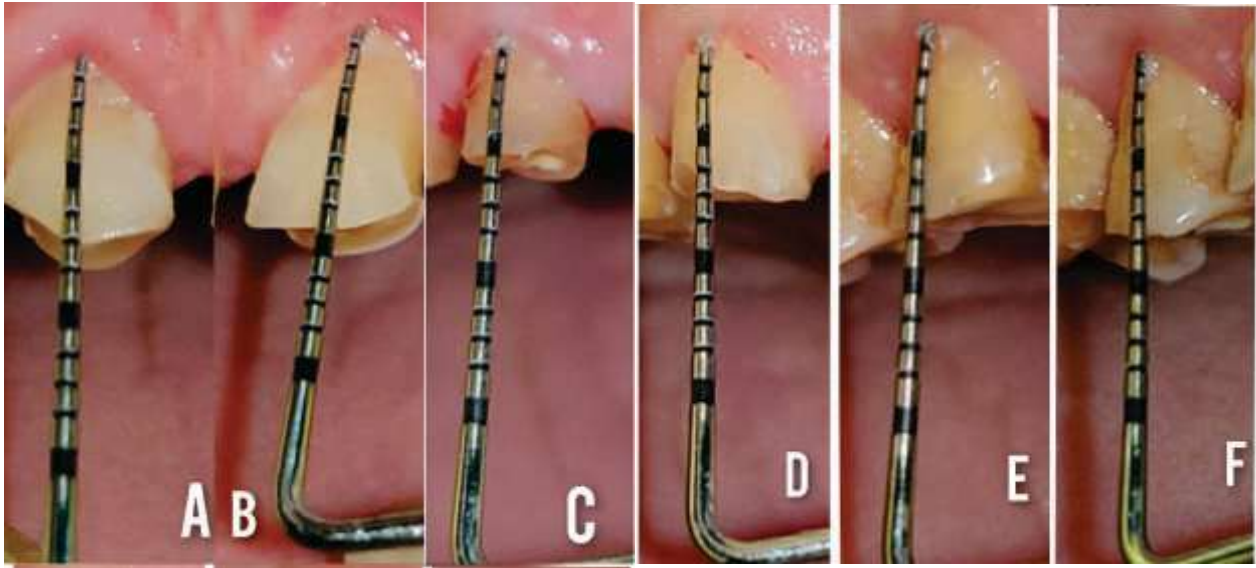


FIG:16-
POST- OPERATIVE
A: Crown length irt 11 is 7 mm
B: Crown length irt 21 is 8.5 mm
C: Crown length irt 12 is 5 mm
D: Crown length irt 13 is 7mm
E: Crown length irt 14 is 7 mm
F: Crown length irt 15 is 8 mm

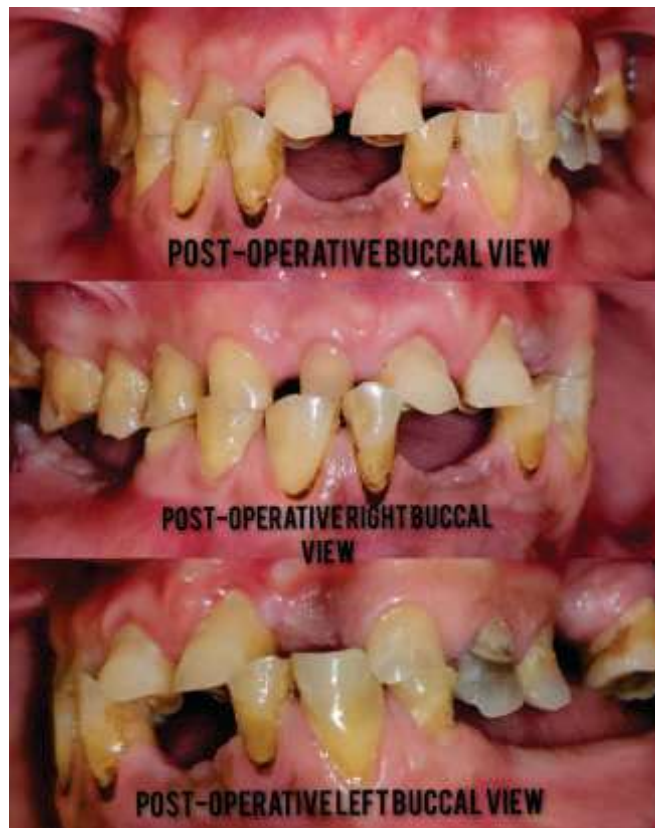

FIG:17- Post-Operative View

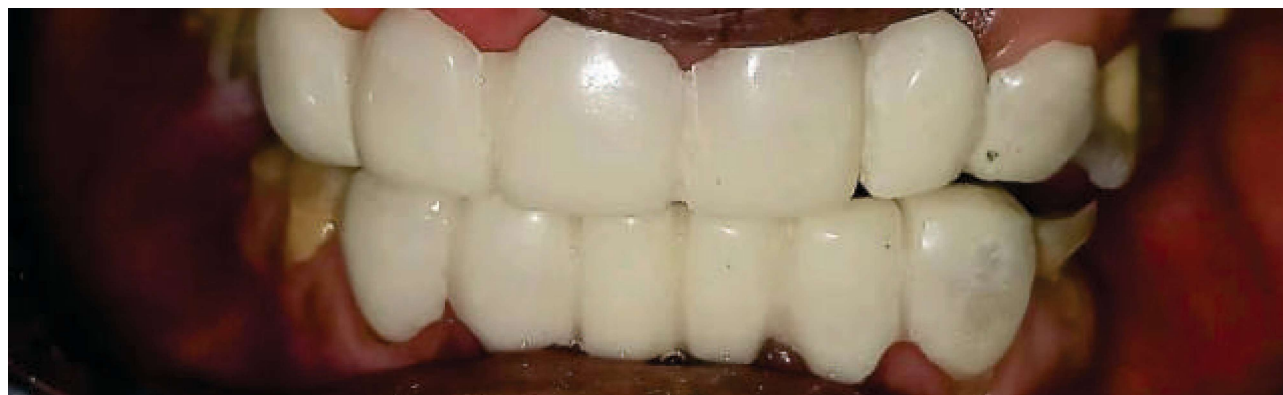

FIG: 18-Temporary Restoration Given

DISCUSSION

Crown lengthening is performed for aesthetic improvement during restorations and in teeth with subgingival caries or fractures; in addition, this surgical procedure can establish an accurate bone width.⁵ Since esthetic crown lengthening surgeries are the elective procedures that aims to improve the appearance of teeth and gums, such procedures are++ interdisciplinary procedures aimed towards full mouth rehabilitation giving good esthetic and functional clinical outcomes. The clinician should make it clear that crown lengthening surgery for sound teeth is limited by a certain length of teeth, which cannot be exceeded.^{6,7}

The esthetic crown lengthening requires gingivectomy procedures to expose the needed additional tooth structure; therefore, a minimum of 2 to 5 mm of keratinized tissue is necessary to ensure the gingival health.^{8,9} Moreover, the management of the papilla is another important aspect of the surgery. The interproximal bone should be carefully removed in order to maintain the anatomic structures, so that the interproximal tissues are allowed to coronally proliferate; the

papilla should replace the distance from the bone crest to the base of the contact area (about 5 mm or less).^{10,11} To have a harmonious and successfully long-term restoration, the distance between the crestal bone and prosthetic margins, which allows recreating the biological width, should be at least 3 mm.¹² Several studies suggest that the biologic width reestablishes itself after crown lengthening procedures, in 6 months.¹³⁻¹⁶ For this reason, in this present case report the Placement of definitive prosthesis was carried out after the complete healing of gingiva in order to obtain the aesthetic position of the prosthetic margin.

CONCLUSION

Crown lengthening surgery is a viable option for facilitating restorative therapy or improving esthetic appearance. However, to plan crown lengthening procedure, the whole periodontal condition of the patients and their hygiene habits should be evaluated first. The selection of the appropriate technique depends on the clinician's personal preferences and experiences. Out of the array of different techniques the clinician applies and modifies them depending on the case.

REFERENCES

- 1- American Academy of Periodontology. Glossary of Periodontal Terms. 4th ed. Chicago: American Academy of Periodontology; 2001. p. 11.
- 2- A. W. Gargiulo, F. M. Wentz, and B. Orban, "Dimensions and relations of the dentogingival junction in humans," *Journal of Periodontology*, vol. 32, no. 3, pp. 261–267, 1961.
- 3- J. S. Ingber, L. F. Rose, and J. G. Coslet, "The 'biologic width': a concept in periodontics and restorative dentistry," *Alpha Omegan*, vol. 70, no. 3, pp. 62–65, 1977.
- 4- K. Pradeep, N. Patil, T. Sood, U. Akula, and R. Gedela, "Full mouth rehabilitation of severe fluorozed teeth with an

- interdisciplinary approach (6 handed dentistry),” *Journal of Clinical and Diagnostic Research*, vol. 7, no. 10, pp. 2387–2389, 2013.
- 5- K. Pradeep, N. Patil, T. Sood, U. Akula, and R. Gedela, “Full mouth rehabilitation of severe fluorozed teeth with an interdisciplinary approach (6 handed dentistry),” *Journal of Clinical and Diagnostic Research*, vol. 7, no. 10, pp. 2387–2389,2013.
 - 6- Allen EP. Use of mucogingival surgical procedures to enhance esthetics. *Dent Clin North Am* 1988 Apr;32(2):307-30.
 - 7- Magne P, Gallucci GO, Belser UC. Anatomic crown width/length ratios of unworn and worn maxillary teeth in white subjects. *J Prosthet Dent*2003 May;89(5):453-61.
 - 8- N. P. Lang and H. Loe, “The relationship between the width of “keratinized gingiva and gingival health,” *Journal of Periodontology*, vol. 43, no. 10, pp. 623–627, 1972.
 - 9- J. G. Maynard Jr. and R. D. Wilson, “Physiologic dimensions of the periodontium significant to the restorative dentist,” *Journal of Periodontology*, vol. 50, no. 4, pp. 170–174, 1979.
 - 10- J. C. Kois, “Altering gingival levels: the restorative connection part I: biologic variables,” *Journal of Esthetic and Restorative Dentistry*, vol. 6, no. 1, pp. 3–7, 1994.
 - 11- D. P. Tarnow, A. W. Magner, and P. Fletcher, “The effect of the distance from the contact point to the crest of bone on the presence or absence of the interproximal dental papilla,” *Journal of Periodontology*, vol. 63, no. 12, pp. 995–996, 1992.
 - 12- U. Bragger, D. Lauchenauer, and N. P. Lang, “Surgical lengthening of the clinical crown,” *Journal of Clinical Periodontology*, vol.19, no. 1, pp. 58–63, 1992.
 - 13- S. K. Lanning, T. C. Waldrop, J. C. Gunsolley, and J. G. Maynard, “Surgical crown lengthening: evaluation of the biological width,” *Journal of Periodontology*, vol. 74, no. 4, pp. 468–474,2003.
 - 14- G. Carnevale, S. F. Sterrantino, and G. Di Febo, “Soft and hard tissue wound healing following tooth preparation to the alveolar crest,” *The International Journal of Periodontics & Restorative Dentistry*, vol. 3, no. 6, pp. 36–53, 1983.
 - 15- E. Oakley, I.-C. Rhyu, S. Karatzas, L. Gandini-Santiago, M.Nevins, and J. Caton, “Formation of the biologic width following crown lengthening in nonhuman primates,” *International Journal of Periodontics and Restorative Dentistry*, vol. 19, no. 6, pp. 529–541, 1999.
 - 16- H.-W. Seol, J.-Y. Koak, S.-K. Kim, and S.-J. Heo, “Full mouth rehabilitation of partially and fully edentulous patient with crown lengthening procedure: a case report,” *Journal of Advanced Prosthodontics*, vol. 2, no. 2, pp. 50–53, 2010.