

\*Tanushri Mehd, \*\*Hirwa Kothari, \*\*\*Dhwanit Thakore, \*\*\*\*Archita Kikani

### ABSTRACT

Peri-implantitis has always been one of the most important biological complication of dental implants. It is proved to be inflammatory in nature and associated with the plaque accumulation in the peri - implant tissues. It can progress on the basis of several factors like the bad oral hygiene habits and also the comorbidity factors. Different treatment modalities are being discussed over a period of last 30 years with the surgical as well as non - surgical methods having their own advantages and disadvantages. In this case report, we describe a case report with a non - surgical treatment approach to treat peri-implantitis with the protocol based on the application of the mechanical as well chemical debridement and use of systemic antibiotics over a period of time. The case showed good results with absence of clinical signs of inflammation with the help of clinical assessments (probing depth, bleeding or suppuration, color of the mucosa and the presence of pain.)

**Keywords:** Peri-implantitis, Non-surgical therapy, Subgingival irrigation, Systemic antibiotics

### INTRODUCTION:

Over last 30 years, dental implants have evolved to be the most effective treatment for partial and complete edentulous arches, that provides masticatory function as well as esthetics. Moreover, in last few decades with the spread of dental implants, it has also come into light the importance of preventing, diagnosing and treating the peri-implant diseases. [1-5]

Under the term peri-implantitis, there's plaque associated pathological condition of the peri-implant tissues, which is characterized by inflammation of mucosa with progressive bone loss near the dental implants in the absence of signs such as bleeding or suppuration during the probing, the diagnosis can be done with the combination of following criteria: depth of probing not less than 6mm, appearance of bleeding or suppuration during this measurements, bone loss level with apical direction not less than 3mm. [6-8] As per the prevalence of peri-implantitis, during the first ten years after the placement of implant it varies from one person to 47 person as per the systemic review of Derks and Tomasi(2015) and also about 85% as per the work of Dreyer(2018) [9-10], specially with the poor oral hygiene, habits like smoking and comorbidity conditions.

As per different clinical trials and reviews, the method of treatment will be multiple stage

protocol which includes treatment of acute inflammation with the help of systemic antibiotics, mechanical and chemical disinfection of implant surface in order to achieve sufficient implant stability and later reconstructive surgery if required [8].

The aim of this article is to present a clinical situation of peri-implantitis and to explain the opportunity of using non-surgical methods with relatively satisfying results with proper function and esthetics

**Case report:** A 37 years old female patient presented at the Department of Periodontics and Oral Implantology, Ahmedabad Dental College and Hospital, reporting with mild pain and bleeding while performing oral hygiene measures at the site of implants placed in mandible for more than 4 years.

The patient was systemically healthy and a non-smoker and gave the informed consent send for the diagnostics, treatment and use of photographs. Clinical examination showed that patient was rehabilitated with a fixed prosthesis supported by two implants in the anterior mandible. The peri-implant mucosa surrounding the implants in 32 and 42 position on visual examination showed signs of inflammation (redness and swelling) as shown in figure 1. More than 4mm of probing depth and presence of bleeding on probing, tissue retraction and suppuration were also observed.

\* PG Student, \*\*PG Student, \*\*\*Reader, \*\*\*\*Professor

DEPARTMENT OF PERIODONTICS AND ORAL IMPLANTOLOGY  
AHMEDABAD DENTAL COLLEGE & HOSPITAL, TA. KALOL, DIST: GANDHINAGAR, GUJARAT, INDIA

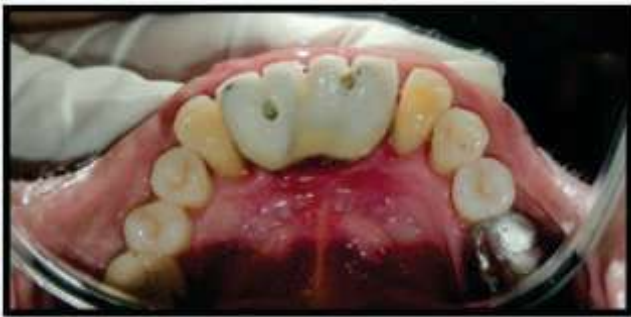ADDRESS FOR AUTHOR CORROSPONDENCE : DR. TANUSHRI MEHD, E-mail : tanushri1002@gmail.com Ph: +1 4372614371

Radiographic signs were also seen (figure 2)

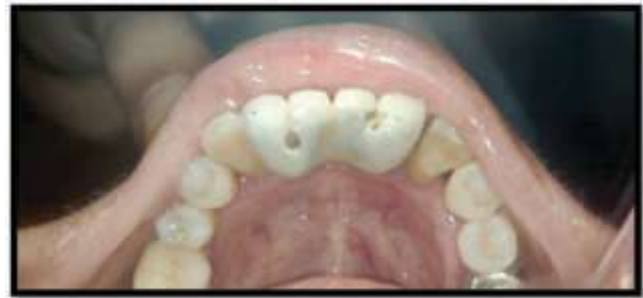The authors decided to perform non-surgical treatment, following the patient's will (who refused surgical treatment at first) and the results were evaluated over time specially the soft tissue healing following the treatment. We proposed the removal of etiologic factors and professional oral hygiene methods to achieve the stability of dental implant. The patient was prescribed with 0.2% chlorhexidine mouth wash to be used for 10 days twice daily. After a period of 7 days, subgingival irrigation with

2% chlorhexidine was done at the site of inflammation. Systemic use of antibiotics (metronidazole 400 mg twice daily) was prescribed for 10 consecutive days.

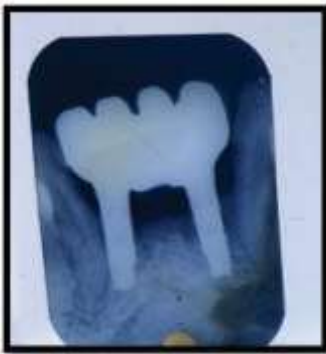At the end of the prescribed treatment the patient presented with significant reduction of inflammatory signs (reduction of probing depth, bleeding on probing, suppuration and tissue retraction). The reduction in radiographic signs were also seen (figure 3 and figure 4).



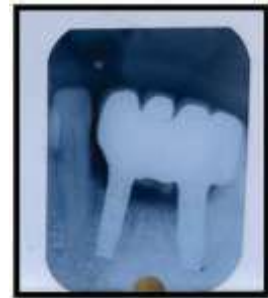**Fig. 1** PRE-OPERATIVE CLINICAL



**Fig. 3** POST-OPERATIVE CLINICAL



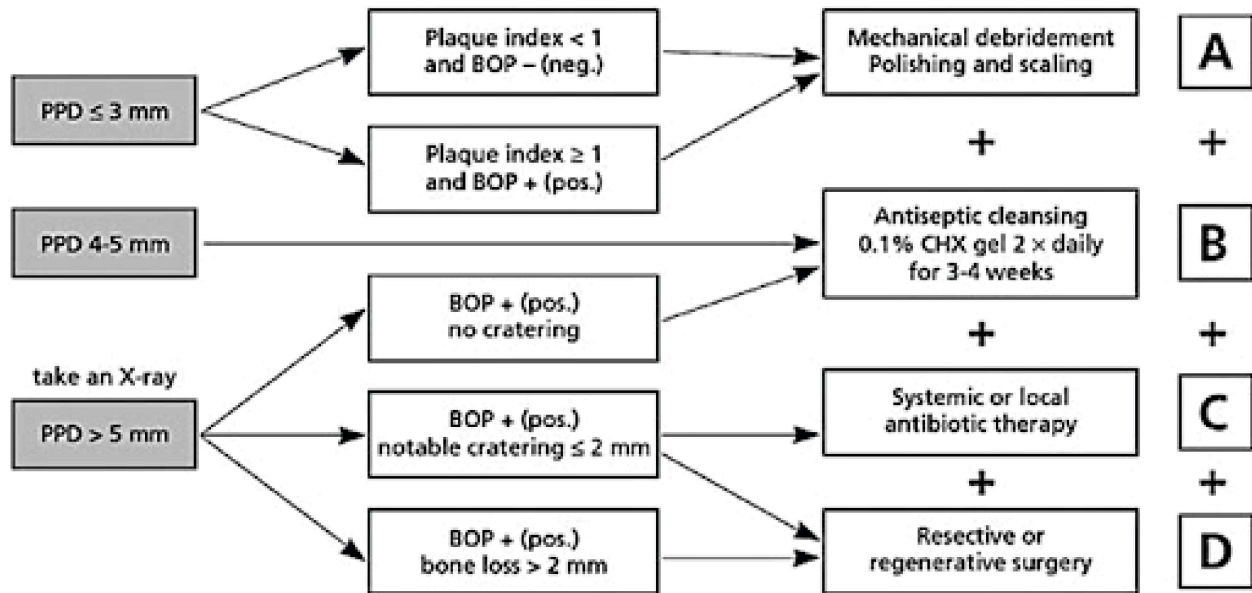
**Fig. 2** OPERATIVE RADIOGRAPHIC



**Fig. 4** POST-OPERATIVE RADIOGRAPHIC

**Discussion:** In the present case, the authors attempted to demonstrate a non-surgical method for the treatment of peri-implantitis which can be easily repeated and made available at all clinics. Constant communication between doctor and patient should be achieved for full compliance and cooperation of the patient during the

treatment. In present case scenario, there was acute abscess like condition so we planned to proceed with non-surgical treatment modality. As there was relief in clinical signs and symptoms we shifted the patient for further on maintenance therapy as per the CIST protocol (Lang et al., 2004)



Placement of dental implant and prosthetic loading leads to bone tissue remodeling and up to some extent of physiological bone resorption. This may depend of presence or absence of micro gap in the system. The bone loss of more than 1mm associates with hidden mucosa inflammation even in condition of absence of clinical signs of mucositis [12].

Poor oral hygiene may lead to formation bacterial plaque near the dental implants which may be a potential predictor for development of mucositis and peri-implantitis [8]. Even after long uneventful period of tissue health it was demonstrated that just 3 weeks without oral hygiene are sufficient to cause peri-implant tissue inflammation with bio film accumulation

and bleeding of probing [13]. The prevalence of mucositis in people that refrained from personal oral hygiene measures was found to be up to 48% [14]. The minimal procedures that can be provided, may include application of subgingival irrigation for control of microbial biofilm and prevention of further spreading of infection. The systemic use of antibiotics for similar purpose were also discussed [11], in a systemic review suarez-lopez del amo f. et al. (2016) analyzed different approaches for periimplantitis and mucositis treatment. Outcomes of non-surgical treatment are effective for decreasing the inflammation, however for regeneration of bone they are less effective [15].

## Conclusion:

Prognosis of the affected implant will be directly related upon the early detection and treatment of peri-implant mucositis and peri-implantitis. Even though the studies dealing with different treatment modalities are not comparable, some clinical improvement emerges with the use of non-surgical therapy in terms of

resolution of inflammation and bone healing. This observation along with our knowledge of indisputable role of periodontal pathogens in the etiology of periimplantitis indicates some form of non-surgical therapy should be incorporated with any other strategy for dealing with this problem.

## REFERENCES

1. Sanz, M.; Newman, M.G.; Nachnani, S.; Holt, R.; Stewart, R.; Flemmig, T. Characterization of the subgingival microbial flora around endosteal sapphire dental implants in partially edentulous patients. *Int. J. Oral Maxillofac. Implant.* 1990, 5, 247–253.
2. Alcoforado, G.A.; Rams, T.E.; Feik, D.; Slots, J. Microbial aspects of failing osseointegrated dental implants in humans. *J. Parodontol.* 1991, 10, 11–18.
3. Meffert, R.M. What causes peri-implantitis? *J. Calif. Dent. Assoc.* 1991, 19, 53.
4. Machtei, E.E. From periodontitis to periimplantitis—The quest for the missing link. *Curr. Oral Health Rep.* 2020, 7, 72–78. [CrossRef]
5. Heitz-Mayfield, L.J.; Heitz, F.; Lang, N.P. Implant disease risk assessment IDRA—A tool for preventing peri-implant disease. *Clin. Oral Implant. Res.* 2020, 31, 397–403. [CrossRef]
6. Mayer, Y.; Ginesin, O.; Horwitz, J. A nonsurgical treatment of peri-implantitis using mechanic, antiseptic and anti-inflammatory treatment: 1-year follow-up. *Clin. Exp. Dent. Res.* 2020. [CrossRef]
7. Jepsen, S. New classification of periodontal and peri-implant diseases and conditions. *Endod. Pract. Today* 2020, 14, 19–24.
8. Berglundh, T.; Armitage, G.; Araújo, M.G.; Avila-Ortiz, G.; Blanco, J.; Camargo, P.M.; Chen, S.; Cochran, D.; Derks, J.; Figuero, E.; et al. Peri-implant diseases and conditions: Consensus report of workgroup 4 of the 2017 world workshop on the classification of periodontal and peri-implant diseases and conditions. *J. Periodontol.* 2018, 89, S313–S318. [CrossRef]
9. Meyle, J.; Casado, P.; Fourmoussis, I.; Kumar, P.; Quirynen, M.; Salvi, G.E. General genetic and acquired risk factors, and prevalence of peri-implant diseases—Consensus report of working group 1. *Int. Dent. J.* 2019, 69, 3–6. [CrossRef] [PubMed]
10. Francetti, L.; Cavalli, N.; Taschieri, S.; Corbella, S. Ten years follow-up retrospective study on implant survival rates and prevalence of peri-implantitis in implant-supported full-arch rehabilitations. *Clin. Oral Implant. Res.* 2019, 30, 252–260. [CrossRef]
11. Wang, J.C.; Wang, H.L. Laser-assisted therapy for peri-implant diseases. In *Lasers in Oral and Maxillofacial Surgery*; Stübinger, S., Klämpfl, F., Schmidt, M., Zeilhofer, H.F., Eds.; Springer International Publishing: Cham, Switzerland, 2020; pp. 123–137. [CrossRef]
12. Araújo, M.G.; Lindhe, J. Peri-implant health. *J. Periodontol.* 2018, 89, S249–S256. [CrossRef] [PubMed]
13. Heitz-Mayfield, L.J.A.; Salvi, G.E. Peri-implant mucositis. *J. Clin. Periodontol.* 2018, 45, S237–S245. [CrossRef]
14. Roos-Jansaker, A.M.; Lindahl, C.; Renvert, H.; Renvert, S. Nine-to fourteen-year follow-up of implant treatment. Part I: Implant loss and associations to various factors. *J. Clin. Periodontol.* 2006, 33, 283–289. [CrossRef]
15. DelAmo, F.; Yu, S.-H.; Wang, H.-L. Non-surgical therapy for peri-implant diseases: A systematic review. *J. Oral Maxillofac. Res.* 2016, 7, 13. [CrossRef]